Three-Dimensional Printing Role in Neurologic Disease

Adrien-Maxence Hespel, DVM, MS

KEYWORDS

• Three-dimensional printing • Rapid prototyping • Presurgical planning
• Stereolithography • Fused deposition modeling

KEY POINTS

- Most commonly in veterinary medicine, 3-dimensional (3D) printing involves the acquisition of raw data using computed tomography MRI or ultrasound. The raw data are processed through different software to create the 3D models.
- Different 3D printing technologies employ various material offering an array of options and cost depending on the purpose of the print.
- 3D printing is used for educational, research and pre-surgical planning purposes.
- 3D printing is becoming a versatile and accessible tool for the clinical floor.

This article, after briefly reviewing the different types of 3-dimensional (3D) printing technologies available and the processes involved in the creation of a prototype, focuses on the applications of 3D models in both human and veterinary neurosurgery.

Currently, 3D images can be created almost instantaneously with the use of advanced imaging technologies such as computed tomography (CT), 4-dimensional ultrasound scan, or MRI. These 3D representations are displayed on computer screens in a 2-dimensional environment but are found to improve surgical planning and the learning experience.[1]

Three-dimensional printing, also known as rapid prototyping, emerged in human medicine in the 1980s. All 3D printing techniques are grouped under the category of additive technologies and are based on the construction of models by addition of successive layers of material on top of the one before. This process could be compared with the construction of toy models using building blocks. The initial additive technology used was a process called *stereolithography* (SL, also known as SLA). Since then, numerous new technologies have emerged and currently include selective laser sintering, multijet modeling, and fused deposition modeling (FDM).[2] This article reviews 2 of the technologies that are most commonly encountered: SL and FDM.

Conflicts of Interest: The author has nothing to disclose.
University of Tennessee, 2407 River Drive, Knoxville, TN 37991, USA
E-mail address: ahespel@utk.edu

Vet Clin Small Anim 48 (2018) 221–229
http://dx.doi.org/10.1016/j.cvsm.2017.08.013
0195-5616/18/Published by Elsevier Inc.
vetsmall.theclinics.com

SL relies on the use of an ultraviolet laser to solidify a liquid acrylic photopolymer, or epoxy resin, contained in a tank. The hardened acrylic is anchored on a build plate, which is lowered at the end of each completed layer so that uncured material remains at the surface to create the upcoming layer. At the time of completion of the model, the build plate is raised, and the surrounding unexposed liquid material is drained. Finally, the model is fully cured in an ultraviolet oven.[3] Selective laser sintering relies on a similar principle, but the raw material is in a powdered form and is being sintered by a high-power laser. The substrate can be plastic, metal, glass, or ceramic and does not require ultraviolet curing.[3]

FDM printers are probably the most widely known, advertised, and accessible printers. They use a roll of raw thermoplastic, commonly polylactic acid (PLA) or acrylonitrile butadiene styrene, which is being fed into a heated extrusion nozzle. When passed in the nozzle, the plastic is melted into a hairlike thin filament, which is then deposited on the build plate 1 layer at a time.

From the data acquisition to the production of the 3D models, there are 4 essential steps.[4]

In the medical field, the data are initially obtained through advanced imaging technologies such as CT, MRI, or ultrasound scan. These techniques are referred to as *transmissive*, and allow the evaluation and reproduction of both the surface and inner structures of an object.[4] In other domains, such as engineering or architectural design, nontransmissive techniques are more common and rely on the use of laser scanners and triangulation. These techniques allow only the surface of an object to be reproduced.[4]

Studies evaluating the ideal parameters for CT acquisition found that data acquired with 2-mm slice thickness, 25% to 75% overlap, and a pitch of 1.5 were adequate for the creation of 3D models.[5–7] However, in the author's experience and in a more recent publication,[8] and with the progression of CT and printer technologies, thinner slices such as 0.65 to 1 mm, provide much more detailed and accurate models. MRI was also evaluated as a way to acquire 3D data but the models created were smaller, more likely to contain artifacts, rougher, and more likely to have a discontinued appearance when compared with models created from CT.[8]

The second step on the path to 3D printing involves the importation and processing of the raw data in a 3D software program. These programs come in a variety of prices and abilities (eg, Mimics, Materialise, Leuven, Belgium and OsiriX, Bernex, Switzerland). After importation, the data to be reproduced are identified and selected based on their density (thresholding) and/or topography (segmentation).[6] These processes allow the elimination of nondesirable information, such as electrocardiogram leads or feces. At this point, a digital 3D mesh is created within the software and is the representation of the structure to be printed under the form of numerous continuous and contiguous polygons (**Fig. 1**).[9] The number of polygons directly influences the resolution of the model; an increase in the number of polygons results in an improvement in resolution. However, this improvement also results in an increase in computational power needs.

The third step is focused on optimization and depends on the prototype's purpose and the printer's potential limitations. The most common alterations are edge smoothing and reducing the object's size to fit the printer's build envelope. After being created, the mesh is exported as a CAD (computer-aided design) or an STL (surface tessellation language) file.

Lastly, the CAD or STL file is imported into a software program that is able to communicate with the 3D printer such as Makerware (Makerbot, Brooklyn, NY), ReplicatorG (open source) or Cura (Ultimaker, Geldermalsen, Netherlands). In this step,

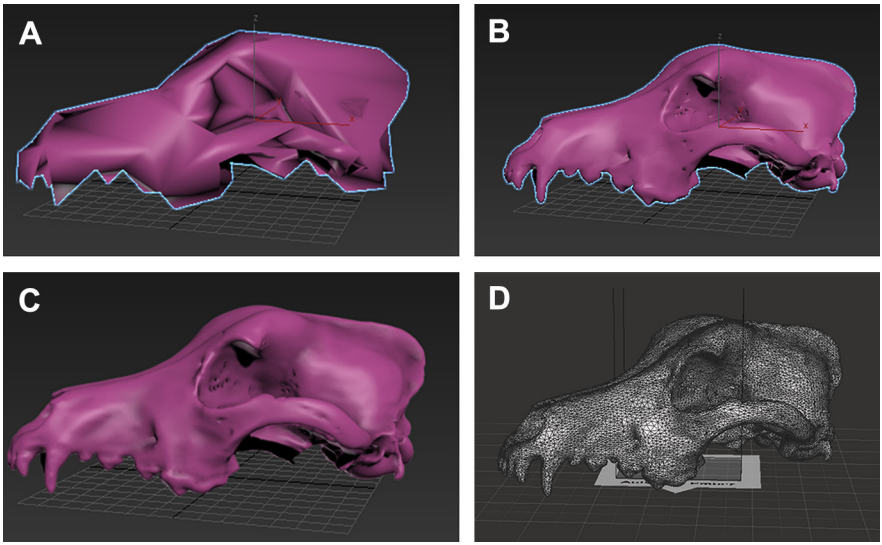

Fig. 1. (*A–D*) Computer rendering of the skull of a skeletally mature dog. Note the increase in resolution from the image A to C. The number of polygons increase from 1000 (*A*), 10,000 (*B*), and 60,000 (*C*). The intricacy of the polygonal mesh is visible (*D*).

the print settings are defined (ie, layer height, temperature of extrusion), the type of material is chosen, and the object is printed.

An inclusive, descriptive tutorial on how to create a 3D model from the CT data acquisition to the final printing step is available online and could be used as a guideline.[9]

From an economical perspective, 3D printers are available in a range of prices. Many of the current consumer grade FDM printers vary between $500 and $2000. Industrial-grade SL printers can reach prices up to $500,000. When considering the purchase of a printer, one needs to consider the type of technology, the size of the building plate, the resolution, and the type of material used to print. SL or selective laser sintering printers represent a higher investment cost, and a higher overall use and maintenance cost, when compared with FDM printers. However, they have the advantage of allowing for the use of a wider range of materials, some of them being Us Food and Drug Administration approved. They also do not always require support material to build the prototype and usually have an overall smoother finish when compared with FDM. On the other hand, FDM printers are more available, easier to use and maintain, and do not require extensive expertise for optimal results.

Printing resolution is commonly as high as 25 to 100 μm. One could think that the higher the printer resolution the better; however, for medical applications, the best currently available clinical CTs have detectors measuring between 500 and 650 μm. Therefore, the CT data are often the limiting factor in the case of rapid prototyping resolution.

It should also be mentioned that multiple companies that specialize in rapid prototyping also offer the services of creating, printing, and shipping the models for a fee.

In human medicine, including neurosurgery, 3 main uses for rapid prototyping have been explored: creation of tailored anatomic models for clinical surgical planning and educational and research prototypes.[10]

Patient-specific models have been extensively used and studied in cases of cerebral aneurysm.[11–20] Those studies found that the models were anatomically accurate when compared with the anatomy visually[16,18,19] and were precise to the millimeter level when analyzed.[18] The use of prototypes allowed for decreased intraoperative time for cases of arteriovenous malformations in pediatric patients.[18] Models have also been used for hemodynamic analysis[13] and flow prediction and for surgical training.[16]

In cases of brain and spinal tumors, 3D models have been used to evaluate the association between neoplastic and adjacent healthy tissues to help delineate margins (osseous, nervous, and vascular).[21,22]

Rapid prototyping has also been used and evaluated for the management of spinal trauma. In trauma cases, it was found that 3D models allowed better and faster identification of complex fractures of the vertebral column when compared with 3D computer renderings and 2D CT images.[23] Neurosurgical guides have been created and evaluated for the placement of screws in the pedicle of thoracic vertebrae with very high accuracy and a deviation averaging less than 1 mm.[24]

Training devices have been created to practice technically challenging surgeries such as the transnasal sphenoid endoscopic approach to pituitary neoplasia[25,26] and also have the potential to be combined with surgical navigation systems.[26,27]

In veterinary medicine to date and to the author's best knowledge, there are no scientific studies focused on the neurosurgical applications of rapid prototyping. However, in the author's experience, multiple uses have been beneficial clinically for neurologic patients and for research purposes.

Spinal applications are aimed at presurgical planning for cases such as atlanto-axial subluxation and spinal fractures. Atlanto-axial subluxation is a challenge to surgically correct in dogs; the patients are usually toy breeds, leaving little room to place stabilizing implants. Many techniques have been described for stabilization of these cases and complications described.[28–34] In the cases that the author experienced, it was the preference of the neurosurgeon to use 2 small plates secured by screws to bridge along the ventral aspect of the atlas and axis (**Fig. 2**). Our protocol

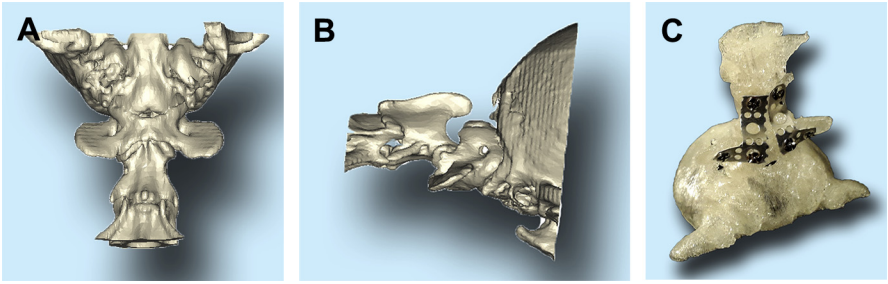

Fig. 2. (*A–C*) Computer-rendered illustrations of a cervical spine affected by atlanto-axial luxation including the caudal aspect of the skull and the cranial aspect of C3, dorsoventral projection (*A*), and right lateral projection (*B*). Dorsoventral view (*C*) of a model of the same cervical spine. Note the 2 bent plates and surgical screws anchored on the ventral aspect of the vertebral bodies of C1 and C2. These plates were used as template for the contouring of the actual surgical plates. Model printed using transparent PLA on a Replicator 2 (Makerbot) with a resolution of 200 μm.

is as follows: the patient undergoes a CT scan of the cervical area, with 0.65-mm slice thickness and pitch of 1.5, and the images are reconstructed in a sharp kernel. After being exported, the model is made based on bone thresholding and segmentation of the spine, including the caudal aspect of the skull and extending caudally up to the midbody of C3. This focused approach allows for a relatively fast printing time, making the technology more clinically available (60–90 min). The models are usually printed in multiple copies. Based on the prototype, the surgical plates or surgical plate templates can be bent to shape and screws chosen and measured to have the optimal length, maximizing bone purchase while avoiding violation of the spinal canal. The evaluation of screw placement can be done directly, as one can visually assess the lumen of the spinal canal of the model. The prototype also allows for surgical training of junior surgeons, surgical practice, and delineation of potential landmarks, to decrease the actual surgery time. Based on personal experience, the surgery time was decreased by 25% to 33% when a neurosurgeon with more than 20 years of experience was provided with the models ahead of surgery.

At the author's current institution, there is research in the development of surgical guides to correct for atlanto-axial instability. The guides are custom made based on the patient's anatomy, sterilized, and used in surgery to guide accurate placement of the surgical implants (**Fig. 3**). The ventral aspect of the guide conforms to the ventral aspect of the vertebral body of C1 and C2. Pipes are created through these guides to provide guidance for surgical pin placement. The pins are later bridged using a resin such as polymethyl methacrylate.

Similar uses can be found in cases of vertebral fractures (**Fig. 4**) or congenital spinal abnormalities that require surgical correction. The model can also be used to determine whether potential surgery is appropriate based on the involved anatomy. Specifically, in a case of comminuted fractures of the axis that was scheduled to undergo surgical fixation, it was deemed that the risks of the surgery outweighed its potential benefits once the model had been examined and the surgical options considered and practiced.

Neuro-oncology applications for 3D printing have also been discovered. A protocol was developed to print brain tumors using a combination of MRI and CT. There were

Fig. 3. Computer-rendered illustrations of a cervical spine and the created guide for surgical pins placement. The guides are custom made based on the patient's specific anatomy to contour the ventral aspect of the vertebral bodies. The directions of the tunnels are determined to provide a safe corridor for pin placement. (*Courtesy of* Dr Kyle Snowdon, University of Tennessee, Knoxville, TN.)

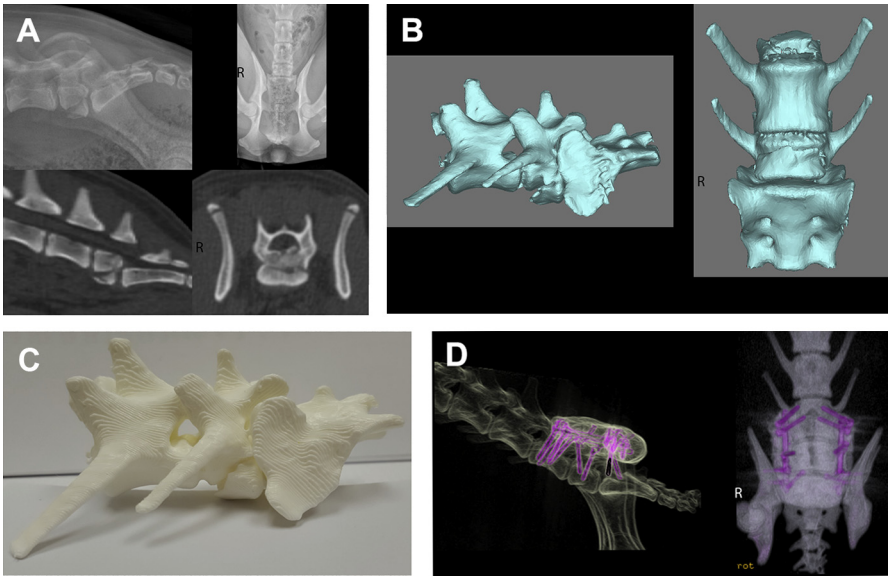

Fig. 4. (*A*) Lateral and ventrodorsal radiographs and multiplanar reconstruction CT images of the lumbar spine of a dog. (*B*) The caudoventral aspect of L6 is fractured and displaced ventrally and cranially. Computer-rendered illustrations of the same spine after 3D rendering. (*C*) Three-dimensional prototype made for presurgical planning, printed with PLA at 200 μm on a Replicator 2. (*D*) Computer-rendered 3D illustration of the postsurgical CT examination. The pins are displayed in pink and are embedded dorsally in polymethyl methacrylate. (*Courtesy of* Dr Kelsey Cline, University of Auburn, Auburn, AL.)

benefits to using this combined modality approach. As brain tumors are not necessarily visible on CT images, and studies have found that MRI tends to create models of reduced size and with more artifacts,[5] a combination of the 2 modalities provides the best compromise. The data pertaining to the osseous structures (ie, cranium, falx cerebri) are acquired using CT for highest accuracy. The data delineating the neoplastic process are acquired using MRI, usually a T1-weighted postcontrast sequence, in combination with other sequences. The 2 data sets are extracted and interpolated into one another (**Fig. 5**), creating one unified set of data. The models created are used for surgical planning in 2 main ways: (1) to delineate potential landmarks for the craniotomy based on the skull morphology and (2) the craniotomy can be performed on the model, and a surgical mesh or plate can be planned to cover the defect in the cranium.

In a similar manner, models of skulls have been printed for multilobular osteochondrosarcoma and osteomyelitis of the cranium (**Fig. 6**). In these cases, the prototypes are used to delineate the extent of the condition and to determine the extent of possible surgical excision. Preplanning of metallic mesh to cover the skull defect is also performed based on the model.

Finally, rapid prototyping technology has been used for research purposes. For example, at the University of Auburn, a research project was conducted to evaluate osseous anomalies of cats affected with gangliosidosis. The models were used to perform measurement of the bones and to compare with healthy specimens at different ages.

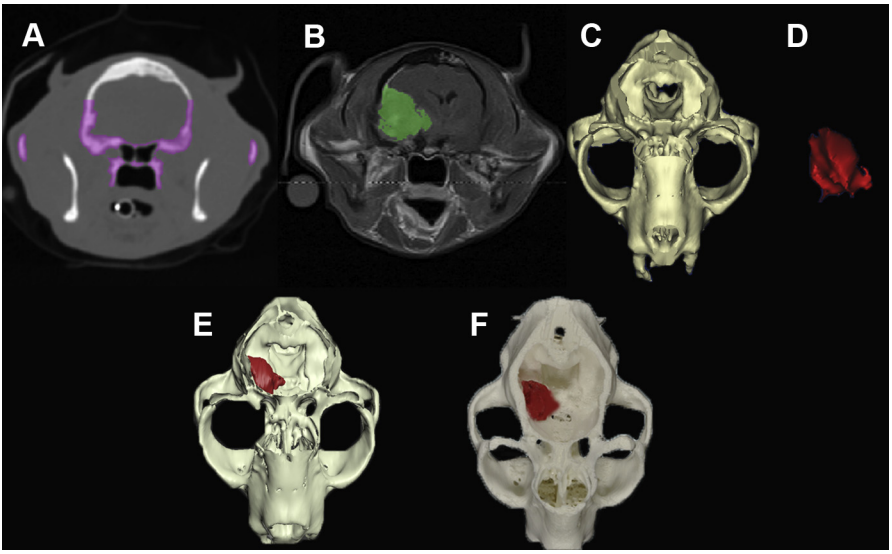

Fig. 5. (*A*) Transverse CT image of the skull of cat at the level of the midbrain. The highlighted in pink parts of the skull are the parts that have been segmented. (*B*) Transverse T1 postcontrast MRI image of the brain of the same cat. The highlighted part in green represents the meningioma as segmented based on the contrast enhancement. (*C*) Computer-rendered 3D illustration of the cranium as delineated in (*A*). (*D*) Computer-rendered 3D illustration of the meningioma as delineated in (*B*). (*E*) The 2 sets of data are interpolated into one another to create a computer-rendered 3D illustration including the skull and the neoplastic tissue accurately. The tumor is displayed in red. (*F*) Three-dimensional printed model of the cranium and extra-axial mass for surgical planning. Model printed using white and red PLA on a Big Builder (Builder 3D, Netherlands); resolution 200 μm.

The advantages of 3D printing are numerous, and its overall low cost is making it an ideal tool to be used clinically and for educational and research purposes. The future of 3D printing will likely be clinical application of printed cells and tissues for reconstructive surgeries, but this process is still in its infancy.

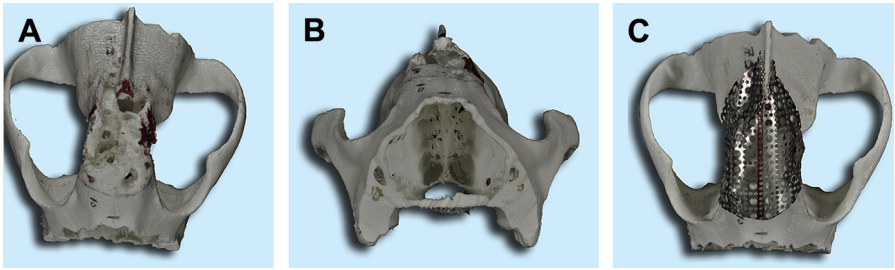

Fig. 6. (*A*, *B*) Three-dimensional model of a dog affected with osteomyelitis secondary to a bite wound. The surgical landmarks for debridement have been delineated. (*C*) A metallic mesh template was created to conform to the ostectomy needed to remove the osteomyelitis.

REFERENCES

1. Hespel AM, Wilhite R, Hudson J. Invited review-applications for 3d printers in veterinary medicine. Vet Radiol Ultrasound 2014;55(4):347–58.
2. Liew Y, Beveridge E, Demetriades AK, et al. 3D printing of patient-specific anatomy: a tool to improve patient consent and enhance imaging interpretation by trainees. Br J Neurosurg 2015;29(5):712–4.
3. McGurk M, Amis A, Potamianos P, et al. Rapid prototyping techniques for anatomical modelling in medicine. Ann R Coll Surg Engl 1997;79(3):169.
4. Corney J, Hieu L, Zlatov N, et al. Medical rapid prototyping applications and methods. Assemb Autom 2005;25(4):284–92.
5. Hopper KD, Pierantozzi D, Potok PS, et al. The quality of 3D reconstructions from 1.0 and 1.5 pitch helical and conventional CT. J Comput Assist Tomogr 1996; 20(5):841–7.
6. Barker T, Earwaker W, Lisle D. Accuracy of stereolithographic models of human anatomy. J Med Imaging Radiat Oncol 1994;38(2):106–11.
7. Lill W, Solar P, Ulm C, et al. Reproducibility of three-dimensional CT-assisted model production in the maxillofacial area. Br J Oral Maxillofac Surg 1992; 30(4):233–6.
8. White D, Chelule K, Seedhom B. Accuracy of MRI vs CT imaging with particular reference to patient specific templates for total knee replacement surgery. Int J Med Robot 2008;4(3):224–31.
9. Doney E, Krumdick LA, Diener JM, et al. 3D printing of preclinical x-ray computed tomographic data sets. J Vis Exp 2013;(73):e50250.
10. Randazzo M, Pisapia JM, Singh N, et al. 3D printing in neurosurgery: a systematic review. Surg Neurol Int 2016;7(Suppl 33):S801.
11. Abla AA, Lawton MT. Three-dimensional hollow intracranial aneurysm models and their potential role for teaching, simulation, and training. World Neurosurg 2015; 83(1):35–6.
12. Thawani JP, Pisapia JM, Singh N, et al. Three-dimensional printed modeling of an arteriovenous malformation including blood flow. World Neurosurg 2016;90: 675–83.e2.
13. Anderson JR, Thompson WL, Alkattan AK, et al. Three-dimensional printing of anatomically accurate, patient specific intracranial aneurysm models. J Neurointerv Surg 2016;8(5):517–20.
14. Ionita CN, Mokin M, Varble N, et al. Challenges and limitations of patient-specific vascular phantom fabrication using 3D Polyjet printing. Proc SPIE Int Soc Opt Eng 2014;9038:90380M.
15. Kondo K, Nemoto M, Masuda H, et al. Anatomical reproducibility of a head model molded by a three-dimensional printer. Neurol Med Chir (Tokyo) 2015;55(7): 592–8.
16. Mashiko T, Otani K, Kawano R, et al. Development of three-dimensional hollow elastic model for cerebral aneurysm clipping simulation enabling rapid and low cost prototyping. World Neurosurg 2015;83(3):351–61.
17. Namba K, Higaki A, Kaneko N, et al. Microcatheter shaping for intracranial aneurysm coiling using the 3-dimensional printing rapid prototyping technology: preliminary result in the first 10 consecutive cases. World Neurosurg 2015;84(1): 178–86.
18. Weinstock P, Prabhu SP, Flynn K, et al. Optimizing cerebrovascular surgical and endovascular procedures in children via personalized 3D printing. J Neurosurg Pediatr 2015;16(5):584–9.

19. Wurm G, Tomancok B, Pogady P, et al. Cerebrovascular stereolithographic biomodeling for aneurysm surgery: technical note. J Neurosurg 2004;100(1):139–45.
20. Xu W-H, Liu J, Li M-L, et al. 3D printing of intracranial artery stenosis based on the source images of magnetic resonance angiograph. Ann Transl Med 2014;2(8):74.
21. Oishi M, Fukuda M, Yajima N, et al. Interactive presurgical simulation applying advanced 3D imaging and modeling techniques for skull base and deep tumors: clinical article. J Neurosurg 2013;119(1):94–105.
22. Spottiswoode B, Van den Heever D, Chang Y, et al. Preoperative three-dimensional model creation of magnetic resonance brain images as a tool to assist neurosurgical planning. Stereotact Funct Neurosurg 2013;91(3):162–9.
23. Li Z, Li Z, Xu R, et al. Three-dimensional printing models improve understanding of spinal fracture—A randomized controlled study in China. Sci Rep 2015;5: 11570.
24. Sugawara T, Higashiyama N, Kaneyama S, et al. Multistep pedicle screw insertion procedure with patient-specific lamina fit-and-lock templates for the thoracic spine: clinical article. J Neurosurg Spine 2013;19(2):185–90.
25. Inoue D, Yoshimoto K, Uemura M, et al. Three-dimensional high-definition neuroendoscopic surgery: a controlled comparative laboratory study with two-dimensional endoscopy and clinical application. J Neurol Surg A Cent Eur Neurosurg 2013;74(06):357–65.
26. Waran V, Menon R, Pancharatnam D, et al. The creation and verification of cranial models using three-dimensional rapid prototyping technology in field of transnasal sphenoid endoscopy. Am J Rhinol Allergy 2012;26(5):e132–6.
27. Waran V, Pancharatnam D, Thambinayagam HC, et al. The utilization of cranial models created using rapid prototyping techniques in the development of models for navigation training. J Neurol Surg A Cent Eur Neurosurg 2014; 75(01):012–5.
28. Beaver DP, Ellison GW, Lewis DD, et al. Risk factors affecting the outcome of surgery for atlantoaxial subluxation in dogs: 46 cases (1978–1998). J Am Vet Med Assoc 2000;216(7):1104–9.
29. Havig ME, Cornell KK, Hawthorne JC, et al. Evaluation of nonsurgical treatment of atlantoaxial subluxation in dogs: 19 cases (1992–2001). J Am Vet Med Assoc 2005;227(2):257–62.
30. Platt SR, Chambers JN, Cross A. A modified ventral fixation for surgical management of atlantoaxial subluxation in 19 dogs. Vet Surg 2004;33(4):349–54.
31. Sanders SG, Bagley RS, Silver GM, et al. Outcomes and complications associated with ventral screws, pins, and polymethyl methacrylate for atlantoaxial instability in 12 dogs. J Am Anim Hosp Assoc 2004;40(3):204–10.
32. Schulz KS, Waldron DR, Fahie M. Application of ventral pins and polymethylmethacrylate for the management of atlantoaxial instability: results in nine dogs. Vet Surg 1997;26(4):317–25.
33. Sorjonen D, SHIRES PK. Atlantoaxial instability: a ventral surgical technique for decompression, fixation, and fusion. Vet Surg 1981;10(1):22–9.
34. Thomas WB, Sorjonen DC, Simpson ST. Surgical management of atlantoaxial subluxation in 23 dogs. Vet Surg 1991;20(6):409–12.