Spinal Cord Diseases

Part 1

Casey P. Neary, DVM, DACVIM (Neurology)
Neurology/Neurosurgery
4/9/17

BUSH VETERINARY
NEUROLOGY SERVICE

About Me….

- Hometown
  - Roswell, GA
- High School
  - Roswell High
- Vet Assistant
  - WHVH
  - Smyrna, GA

BUSH VETERINARY
NEUROLOGY SERVICE

About Me….

- Auburn University
  - B.S.
- University of Georgia
  - DVM
- Cornell University
  - Rotating internship

BUSH VETERINARY
NEUROLOGY SERVICE

About Me….

- Neurology Internship
  - BVNS
  - Springfield, VA
- Residency
  - Neurology
  - Neurosurgery
  - BVNS
  - Leesburg, VA



BUSH VETERINARY
NEUROLOGY SERVICE

The Approach

- Useful for both intracranial and spinal diseases
- The system I use…
  - 4 questions
    - Onset?
    - Progression?
    - Symmetry?
    - Pain / Discomfort?

BUSH VETERINARY
NEUROLOGY SERVICE

The Approach

- Onset?
  - **Peracute**
    - *Hours*
  - **Acute**
    - *Days*
  - **Chronic**
    - *Weeks to months*

BUSH VETERINARY NEUROLOGY SERVICE

The Approach

- Progression?
  - From onset of symptoms
  - **Yes**
  - **No**
    - *Static or improving*

BUSH VETERINARY NEUROLOGY SERVICE

The Approach

- Symmetry?
  - **Symmetric**
  - **Asymmetric**

The Approach

- Painful?
  - **Yes**
  - **No**
  - *What hurts??*
    - Meninges
    - Bone
    - Nerve
    - Muscle
  - *What doesn't??*
    - Spinal cord

BUSH VETERINARY
NEUROLOGY SERVICE

• V	• Vascular
• I	• Infectious / Inflammatory
• T	• Toxin / Trauma
• A	• Anomalous
• M	•
• I	•
• N	• Neoplasia
• D	• Degenerative

BUSH VETERINARY
NEUROLOGY SERVICE

Vascular

- Ischemic myelopathy
- Fibrocartilagenous embolism (FCE)

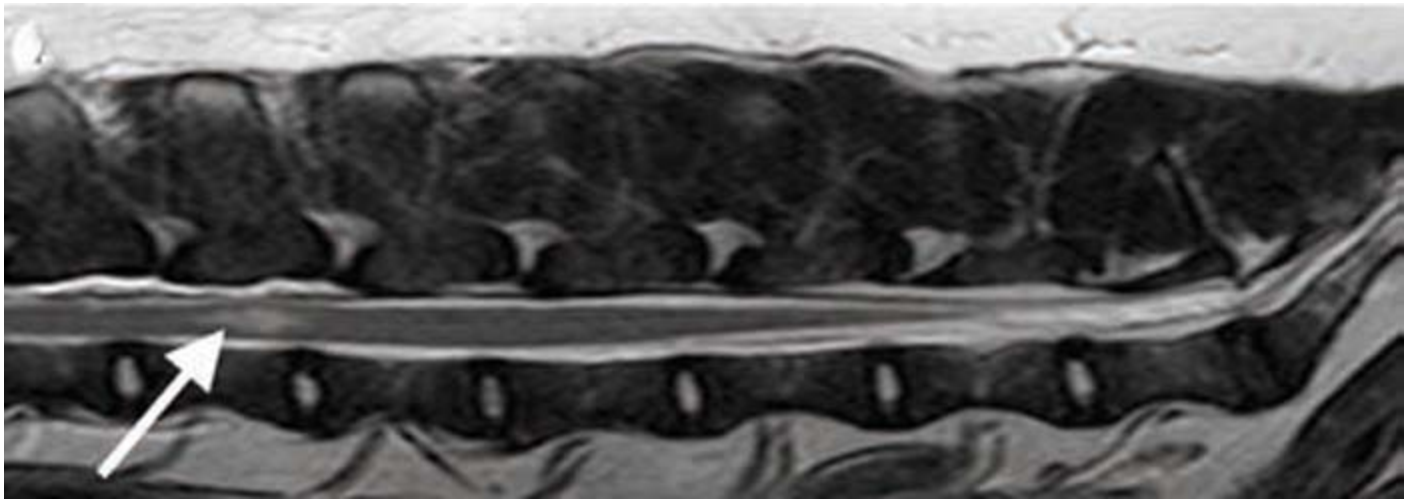

Ischemic Myelopathy

- Anatomy
  - *Ventral spinal artery*
  - *Dorsal spinal arteries*

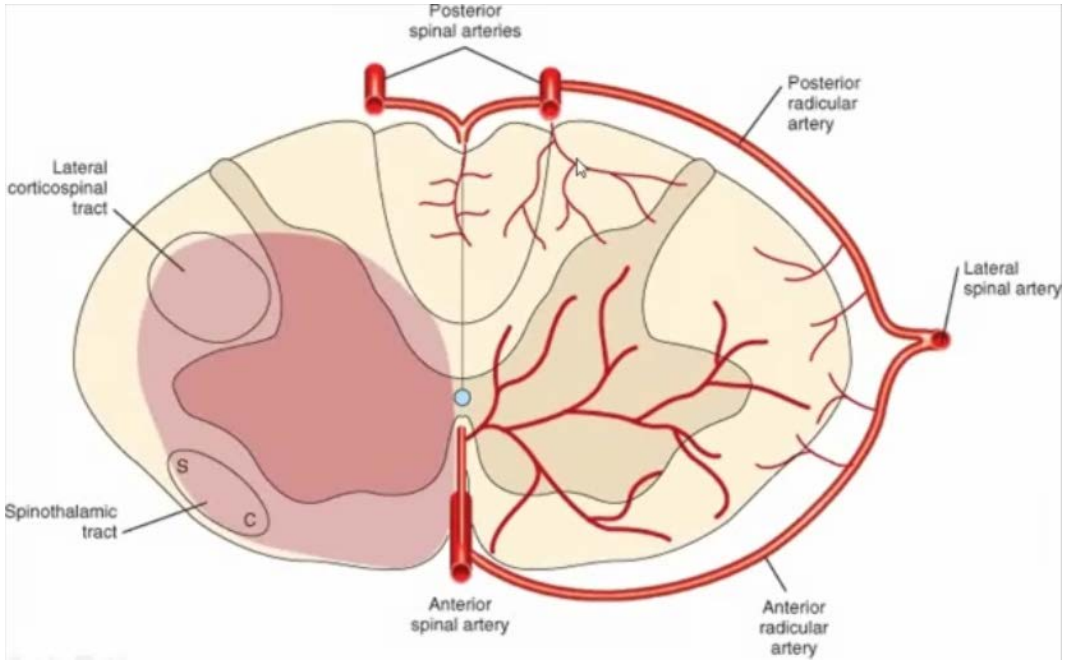

BUSH VETERINARY NEUROLOGY SERVICE

FCE – How??

- Multiple hypotheses
  - *Direct penetration into cord / vasculature*
  - *Neovascularization of disc*
  - *Embryonic vessel*
  - *Herniation into bone?*
    - **Schmorl's node / nodule**

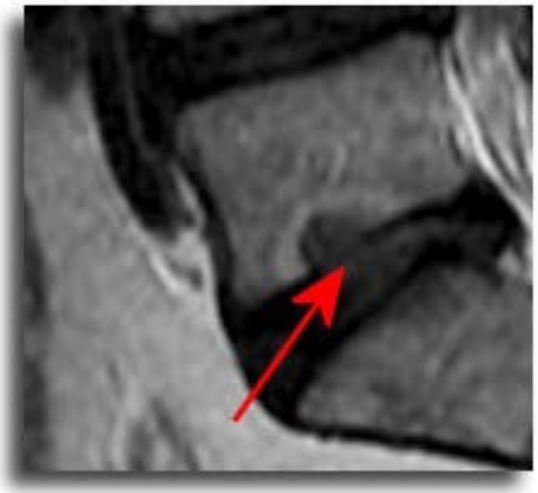

Ischemic Myelopathy

- Signalment
  - Young-to-middle aged dogs
    - Large, giant breeds
    - 80% > 20 kg
  - Exceptions
    - Miniature Schnauzers
    - Irish Wolfhounds

BUSH VETERINARY
NEUROLOGY SERVICE

Ischemic Myelopathy / FCE



- <u>The 4 Questions</u>
  - **Onset?**
    - Peracute (<6 hours)
      - Up to 80% → physical activity
  - **Progression?**
    - Non-progressive
  - **Symmetry?**
    - Very commonly asymmetric
  - **Painful?**
    - Transient pain at onset
    - Non-painful

BUSH VETERINARY
NEUROLOGY SERVICE

Ischemic Myelopathy in Cats??

- Cats?
  - *Less likely fibrocartilage*
  - More commonly
    - Thrombus!
    - Older
    - Concurrent medical conditions
    - Cervicothoracic
      - 60%

BUSH VETERINARY
NEUROLOGY SERVICE

IM in Cats – Cranial Cervical SC

- *J Feline Med Surg 2014*
  - All cats had concurrent illness
  - 6/8 had cervical ventroflexion
  - Mean age of 14 years
  - 3/8 had recurrence

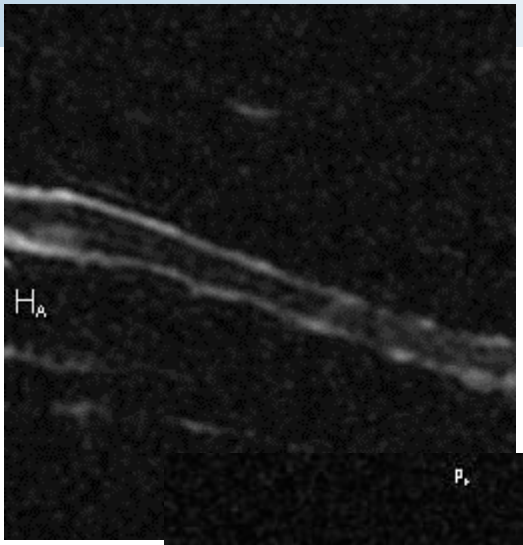

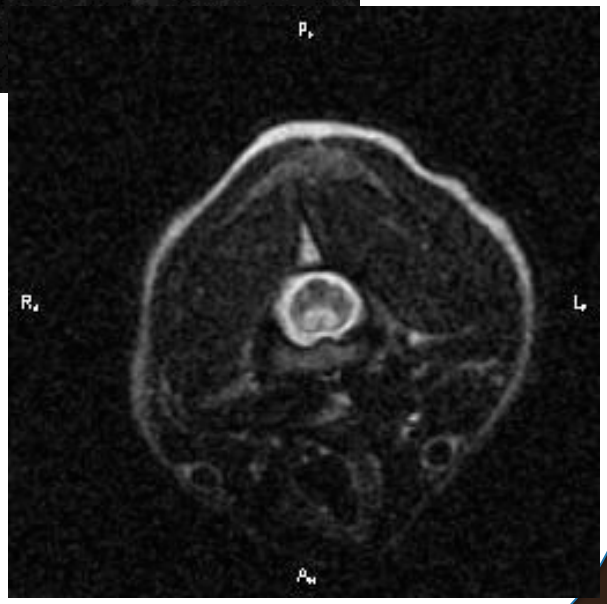

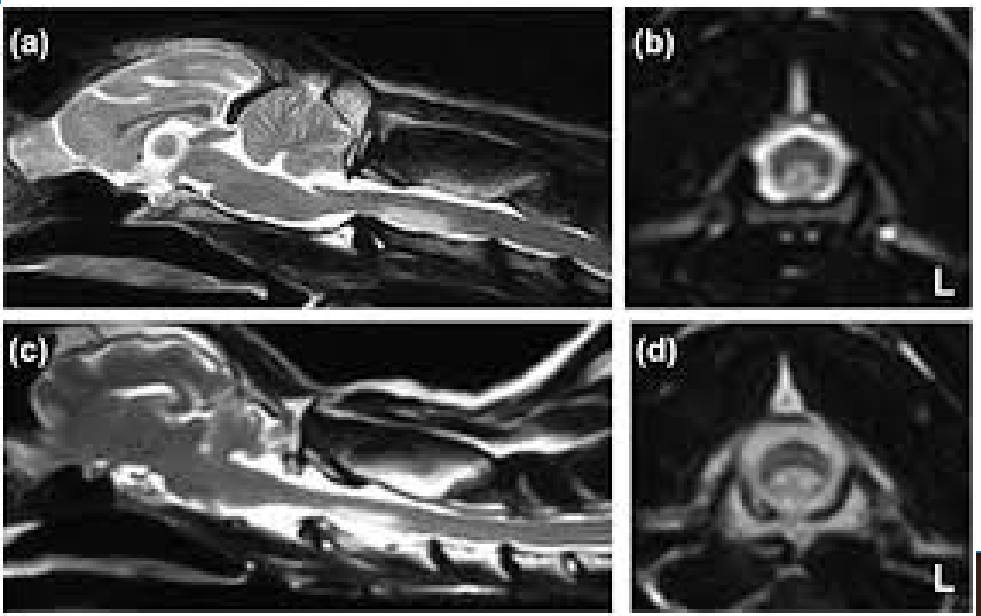

Ischemic Myelopathy

- Diagnostics
  - ****MRI-required diagnosis****
  - CSF analysis
    - Often normal
    - May have elevated
      - Protein
      - RBC
      - WBC

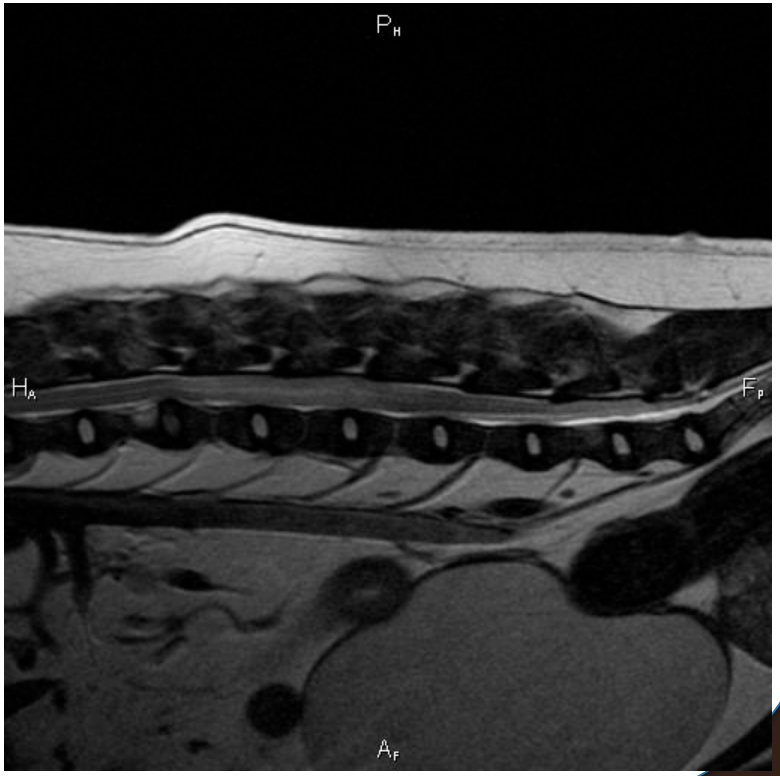

BUSH VETERINARY
NEUROLOGY SERVICE

MRI in Ischemic Myelopathy

- Valuable tool!
  - **Diagnosis**
  - **Prognosis**
- *JAVMA 2008*
  - Vertebral length ratio
    - > 2.0
  - Cross-sectional area
    - > 67%

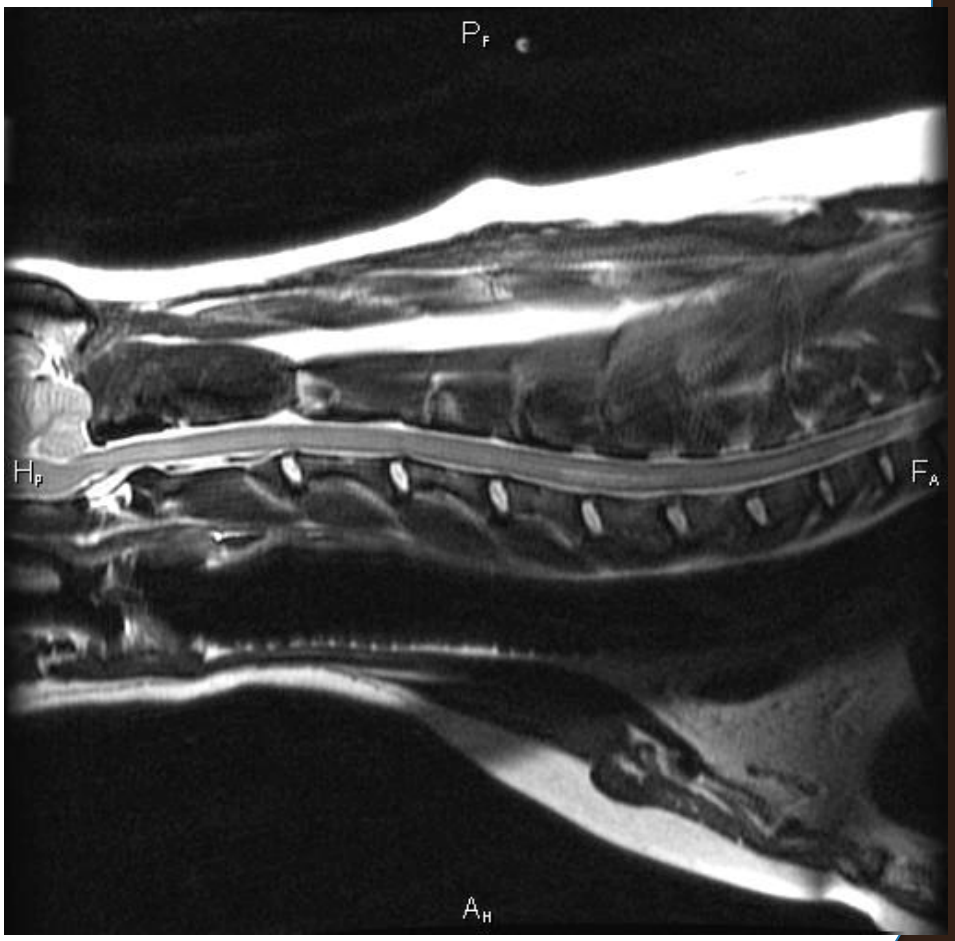

BUSH VETERINARY
NEUROLOGY SERVICE

Ischemic Myelopathy

- Treatment?
  - Supportive care
  - Physical therapy / Rehab
  - *No evidence to support use of NSAID / steroids*

BUSH VETERINARY
NEUROLOGY SERVICE

Ischemic Myelopathy

- Prognosis
  - Good.
    - *84% complete or partial recovery*
  - Negative prognostic factors
    - Neurologic grade
    - LMN signs
      - C6-T2 / L4-S3
    - MRI findings

BUSH VETERINARY
NEUROLOGY SERVICE

- V – Vascular
- I – Infectious / Inflammatory
- T – Trauma
- A – Anomaly
- M – Metabolic
- I – Idiopathic
- N – Neoplasia
- D – Degenerative

Inflammatory Spinal Disease

- Inflammation of nervous tissue or surrounding structures
- Can be broken into 2 categories
  - Infectious
  - Non-infectious
    - Parainfectious
    - Autoimmune
    - Immune-mediated

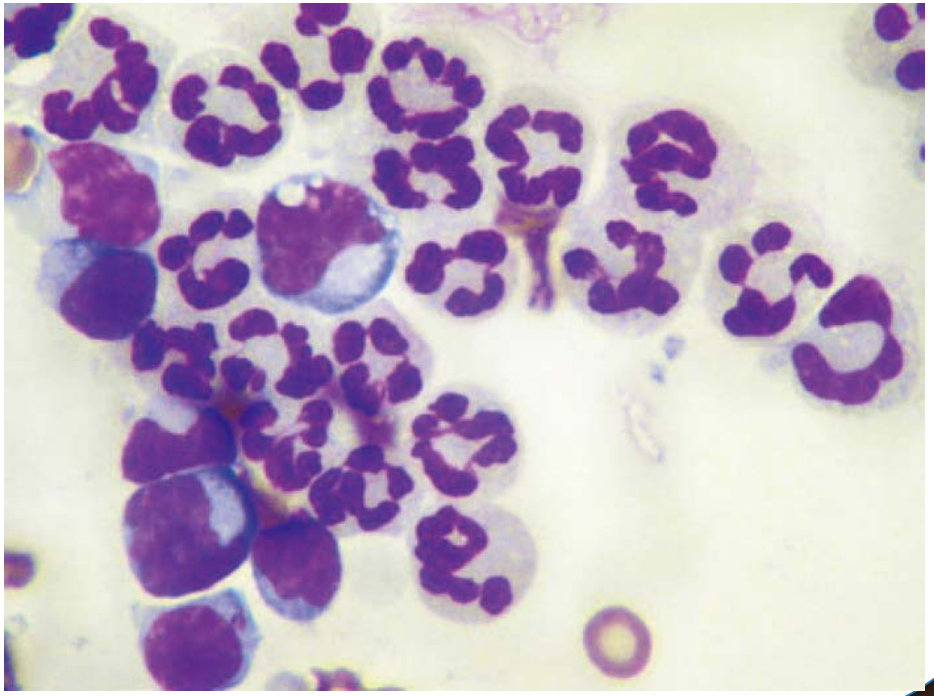

BUSH VETERINARY
NEUROLOGY SERVICE

Infectious Diseases

- Bacterial
- Viral
  - CDV
- Fungal
  - Cryptococcus
- Protozoal
  - Toxoplasma
  - Neospora
- Rickettsial
- Parasitic

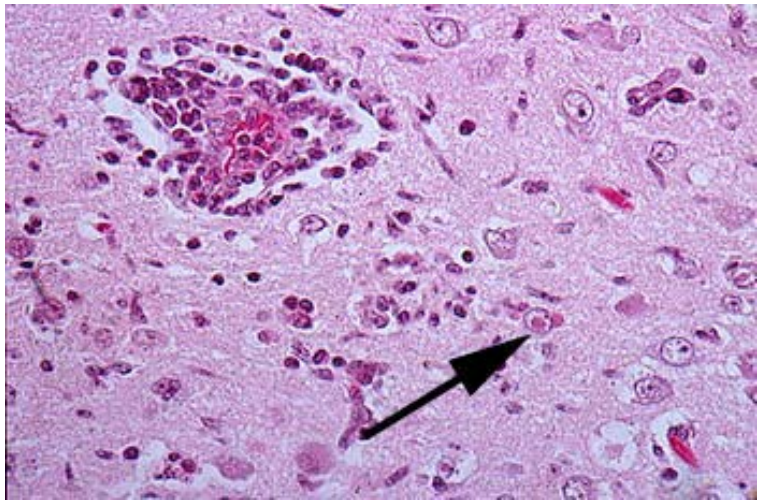

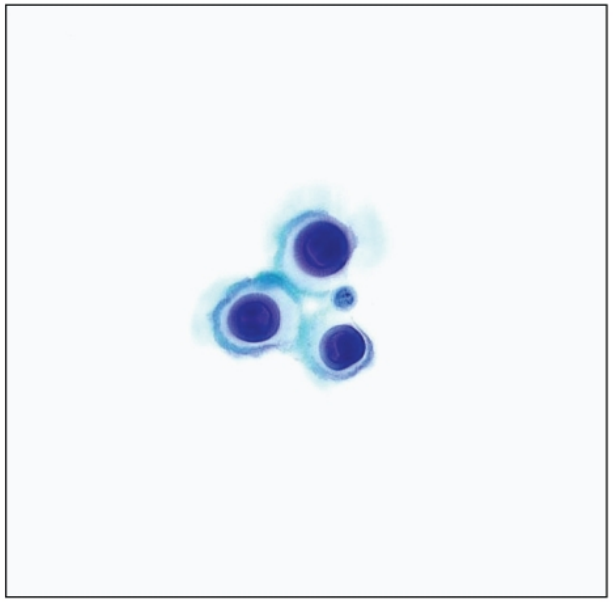

BUSH VETERINARY
NEUROLOGY SERVICE

Diskospondylitis

- Infection of the…
  - Cartilagenous endplates
  - Intervertebral disc
    - *Secondary*
- Source of infection
  - Autogenous
  - Iatrogenic
  - Foreign body

BUSH VETERINARY
NEUROLOGY SERVICE

Diskospondylitis

- Autogenous sources of infection
  - #1 – urinary tract
  - Respiratory
  - Oral cavity
  - Skin
- Infection settles in end plate
  - Blood flow
  - Sinuses / vascular channels

BUSH VETERINARY
NEUROLOGY SERVICE

Pathogens in Diskospondylitis

- Bacterial
  - Most common
    - *Staphylococcus sp.*
    - *Streptococcus sp.*
    - *E. coli*
    - *Brucella*
- Fungal
  - *Aspergillus sp.*

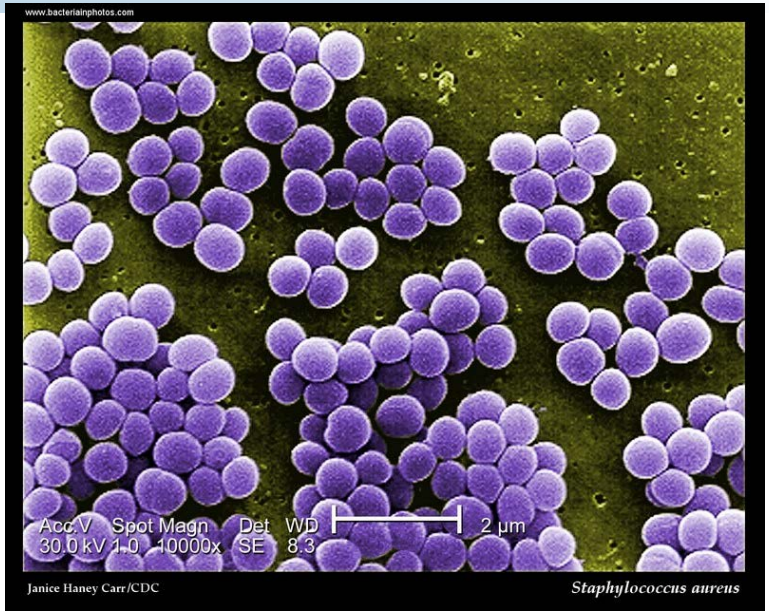

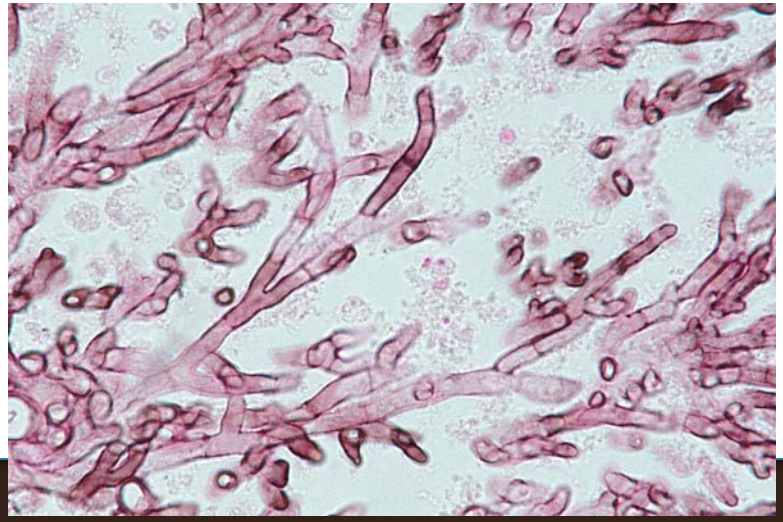

BUSH VETERINARY
NEUROLOGY SERVICE

Diskospondylitis

- Signalment
  - Overrepresentation
    - Breeds
    - Size
    - Age
- Clinical Signs
  - Variable
    - Hyperesthesia most common

BUSH VETERINARY
NEUROLOGY SERVICE

Diskospondylitis

- Diagnostics
  - Numerous modalities
    - Radiographs
    - CT
  - MRI is more sensitive
    - Early in disease
    - Soft tissue changes
  - L7-S1 most common

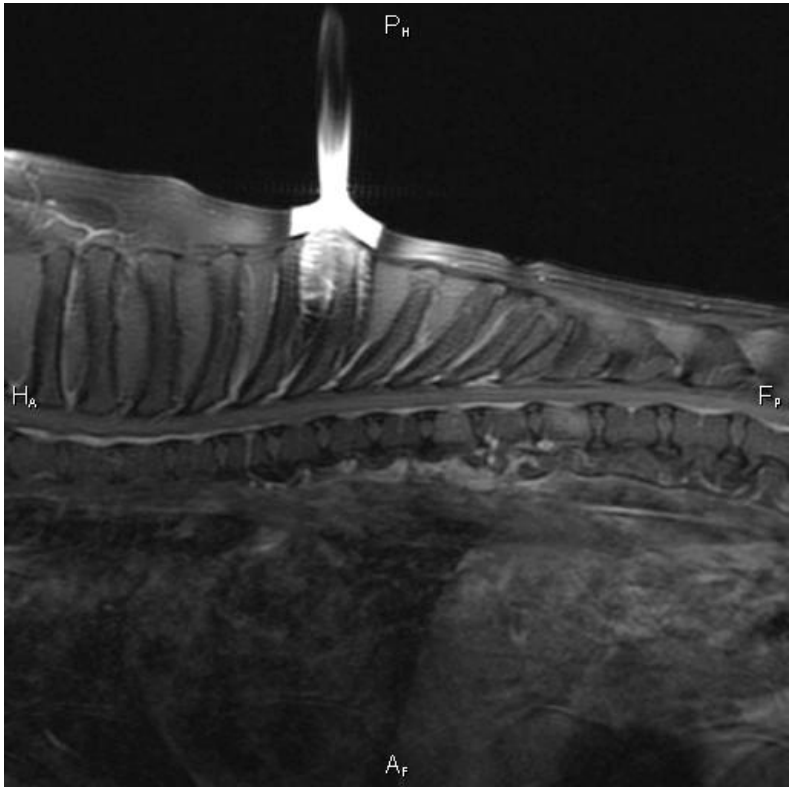

BUSH VETERINARY
NEUROLOGY SERVICE

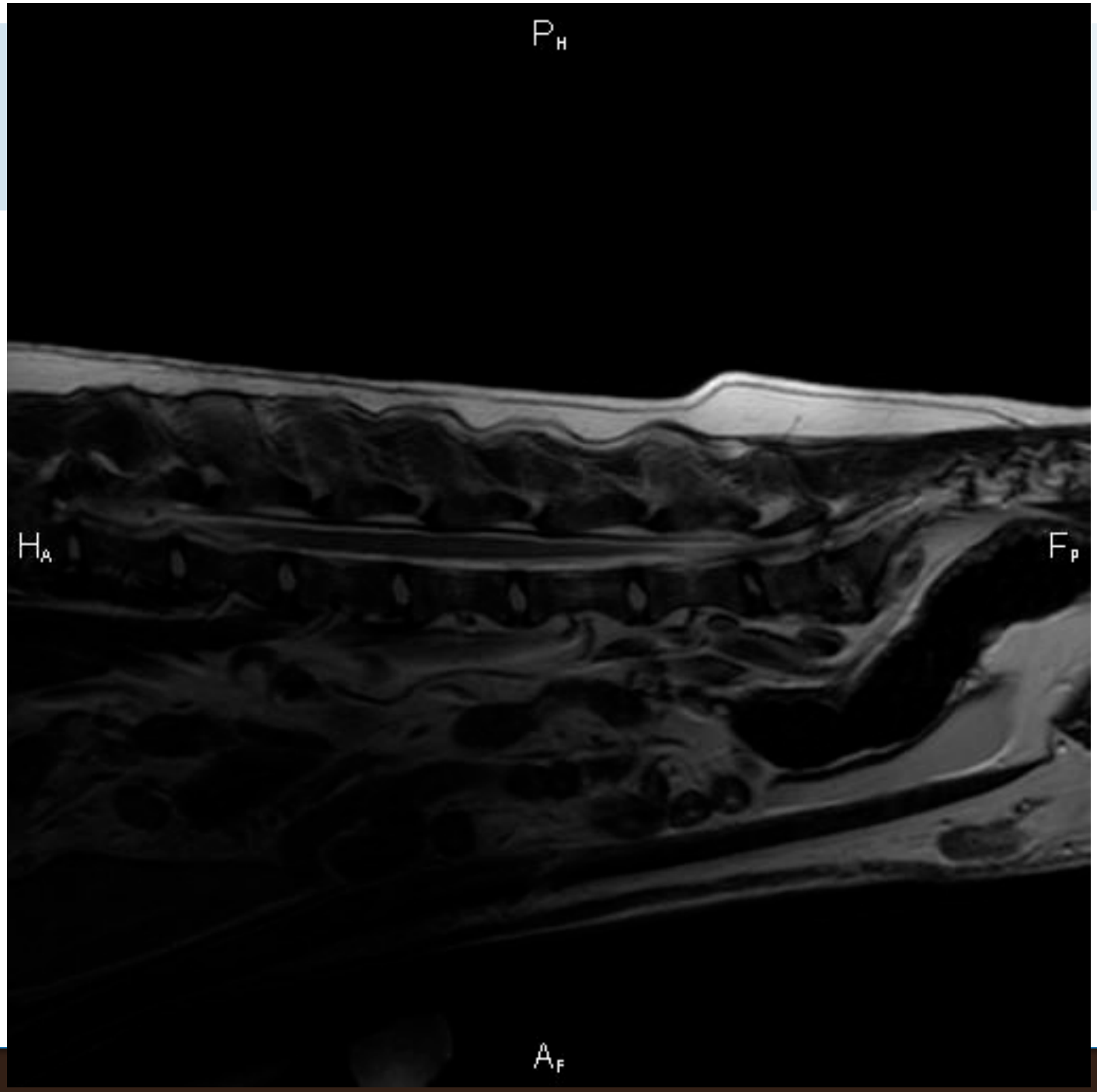
PH
HA
FP
AF

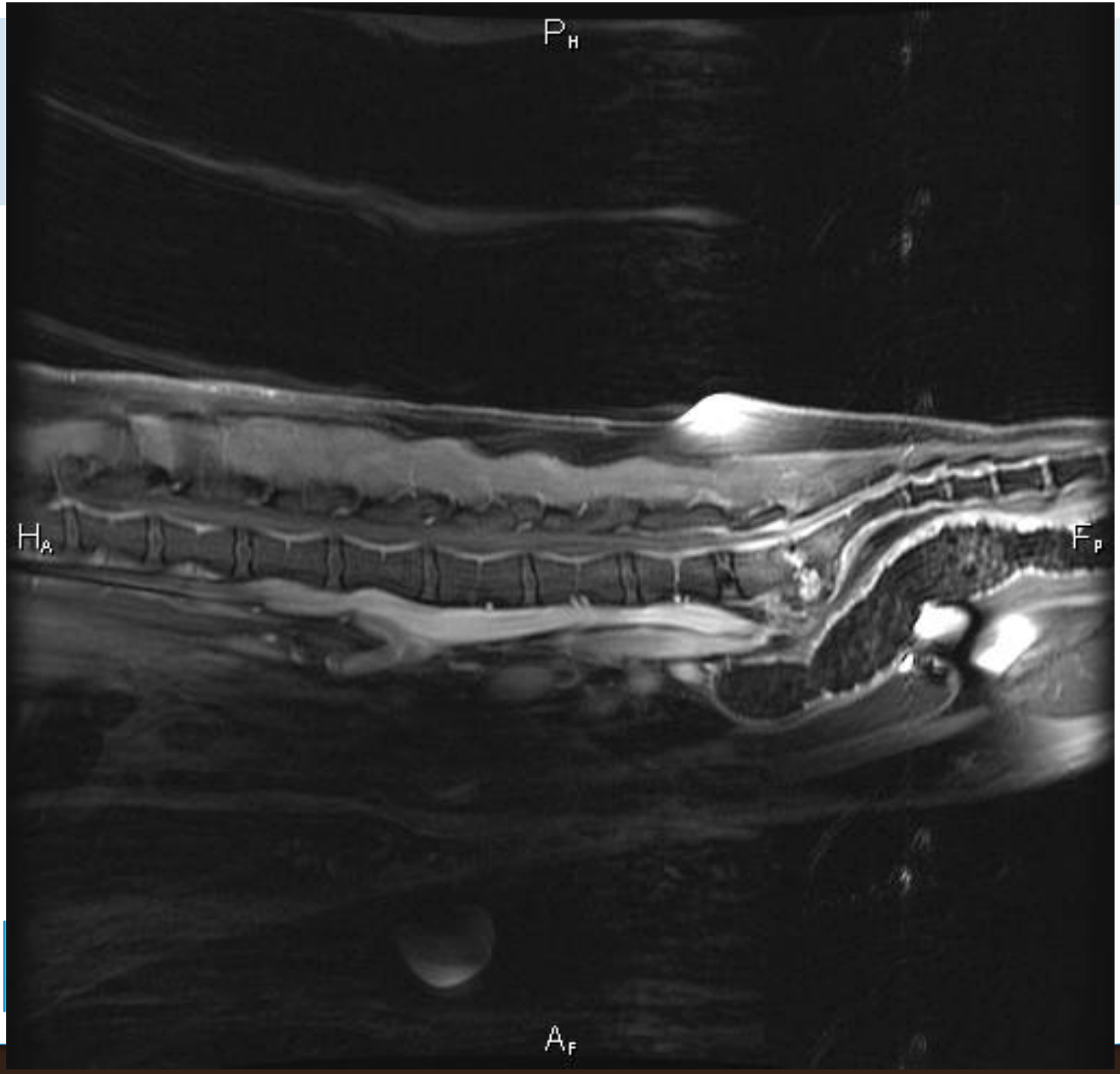
PH
HA
FP
AF

Diskospondylitis Sequelae

- Empyema
  - Most common
  - → compressive myelopathy
- Pathologic fracture

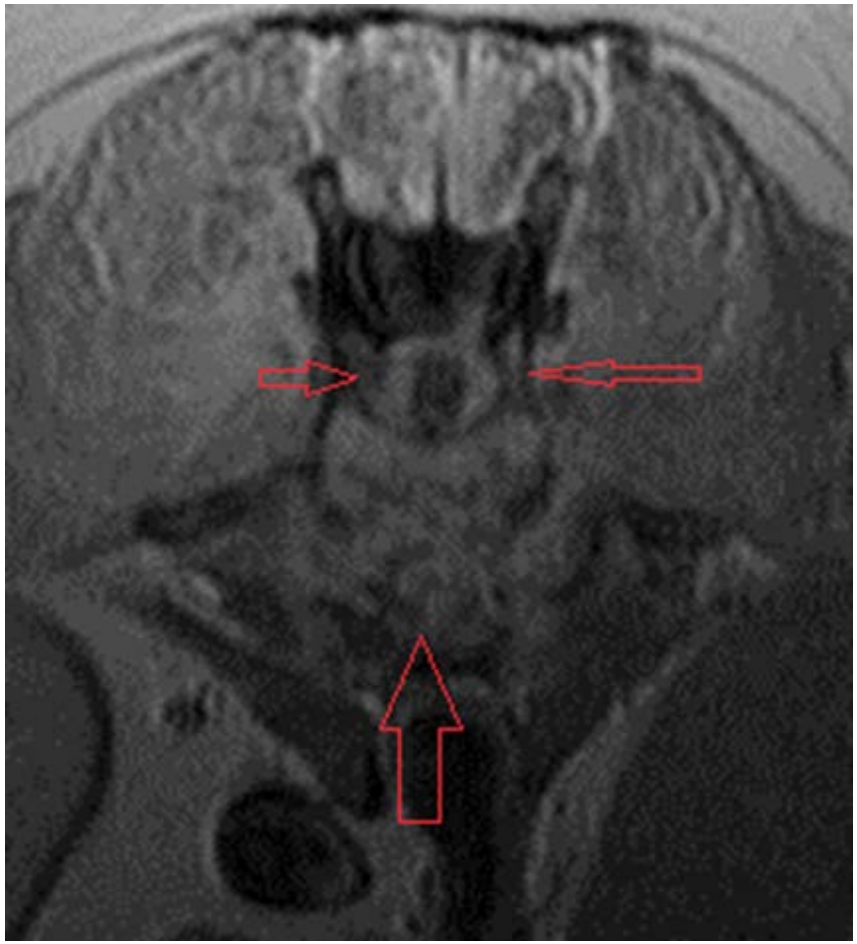

BUSH VETERINARY NEUROLOGY SERVICE

Diskospondylitis

- Ancillary diagnostics
  - CBC / Chemistry
  - Urine culture
  - Blood culture
  - Fungal serology
  - Brucella

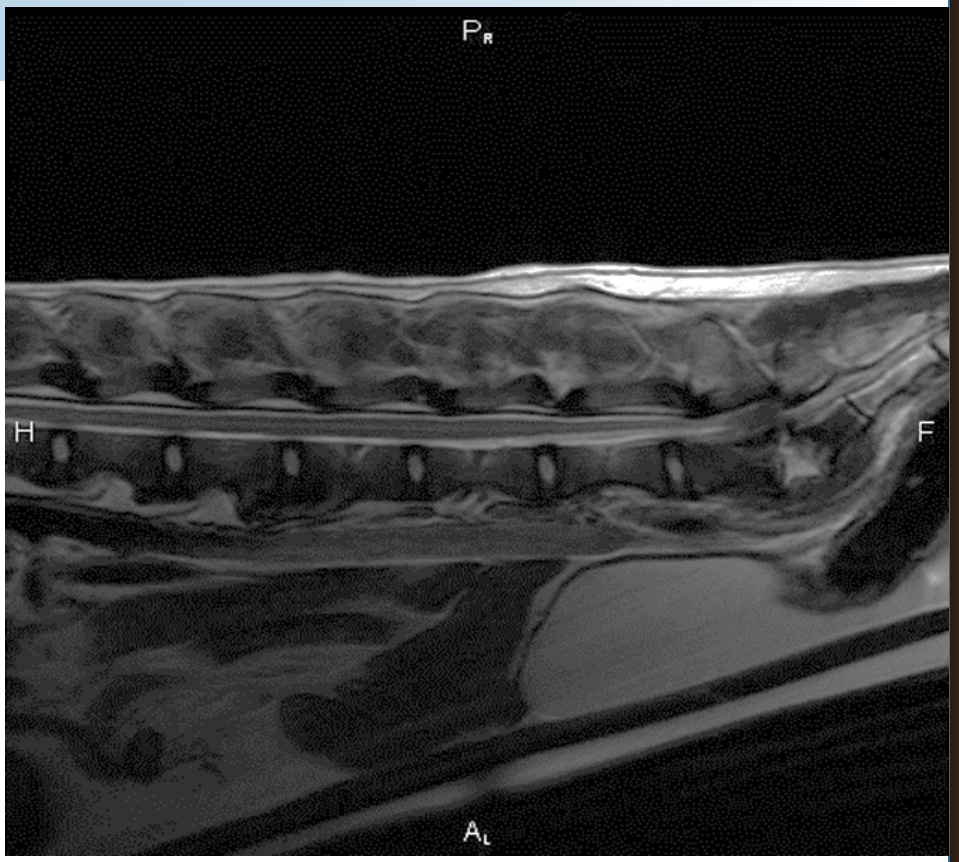

  - ***C-reactive protein***

BUSH VETERINARY
NEUROLOGY SERVICE

Diskospondylitis

- Treatment
  - Ideally based on culture results
    - Broad spectrum antibiotic therapy
      - With good bone penetration
    - Cephalosporins
      - Cephalexin
    - Clindamycin
    - +/- addition of fluoroquinolone
  - Length??

BUSH VETERINARY
NEUROLOGY SERVICE

Diskospondylitis

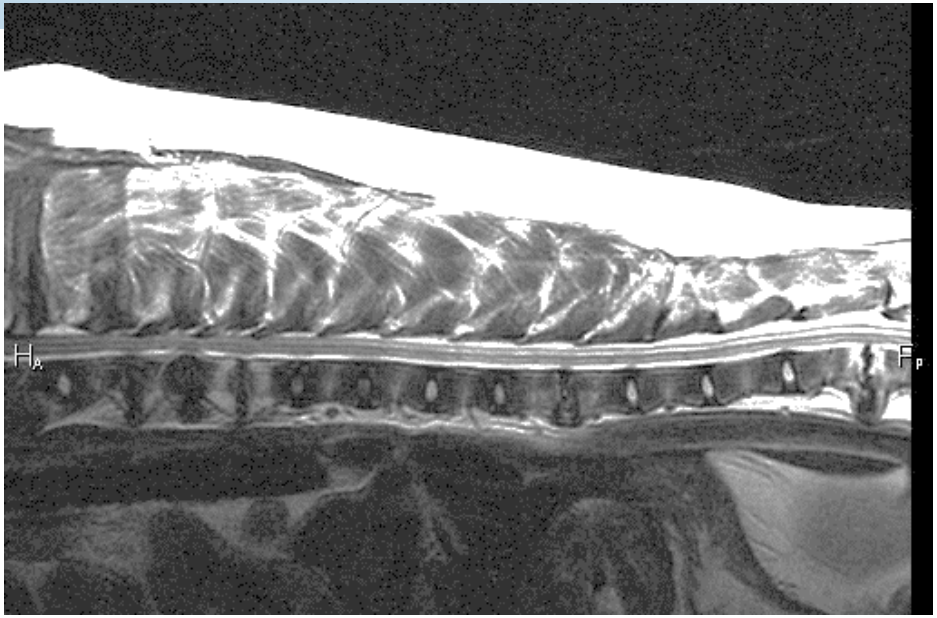

- Prognosis
  - Generally favorable
    - Bacterial
    - 1 site affected
    - Mild deficits
  - Poor
    - Fungal / resistant bacterial
    - Multiple sites
    - Severe deficits

BUSH VETERINARY
NEUROLOGY SERVICE

Diskospondylitis in Cats??

- Sparse case reports
- "Ginger"
  - 8 mo Bengal
  - Reluctant to jump
  - LS pain

BUSH VETERINARY
NEUROLOGY SERVICE

Feline Diskospondylitis

BUSH VETERINARY
NEUROLOGY SERVICE

Feline Diskospondylitis

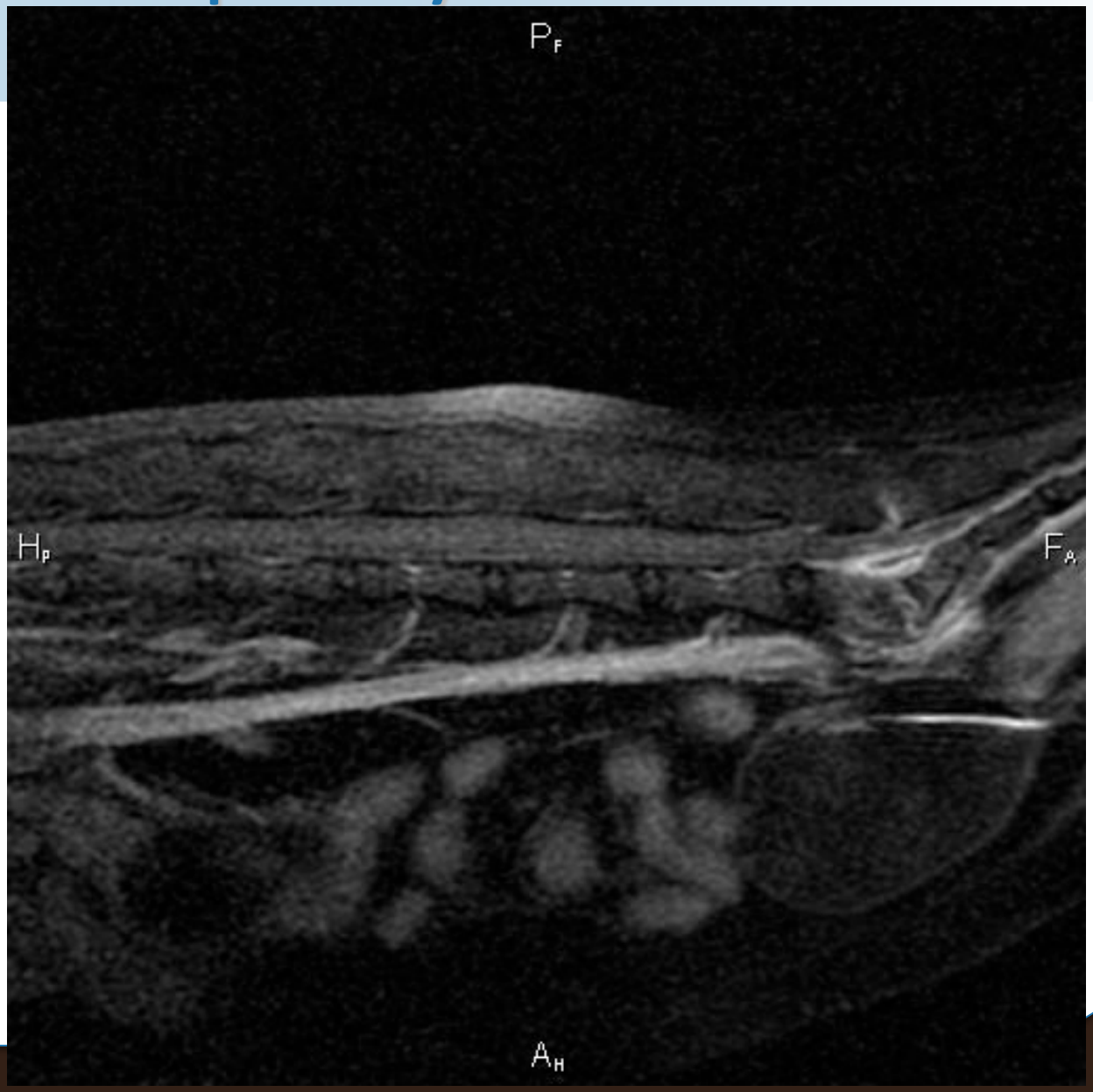

BUSH VETERINARY
NEUROLOGY SERVICE

Diskospondylitis

- The 4 Questions
  - **Onset?**
    - Acute to chronic
  - **Progression?**
    - Progressive
  - **Symmetry?**
    - Symmetric
  - **Painful?**
    - Hallmark of disease

Inflammatory Spinal Disease

- Non-infectious / Immune-mediated
  - Meningomyelitis
    - **MUE / GME**
  - Meningitis / arteritis
    - **SRMA**

BUSH VETERINARY
NEUROLOGY SERVICE

Inflammatory Spinal Disease

- **MUE / GME**
  - Young to middle aged dogs
  - Maltese, Poodle, Lhasa Apso
  - Clinical findings
    - Pain
    - Varying degrees of dysfunction
- **SRMA**
  - Young dogs (~ 8 mo)
  - Boxer, Bernese, Beagle, Lab, GSP
  - Clinical findings
    - Pain (cervical)
    - Fever

BUSH VETERINARY NEUROLOGY SERVICE

MUE / GME

- Diagnostics
  - MRI
    - Focal or multifocal lesions
      - Variable contrast enhancement
    - Meningeal enhancement
  - CSF
    - Abnormal
      - 70-100%
    - Too many cells / high protein
      - Pleocytosis

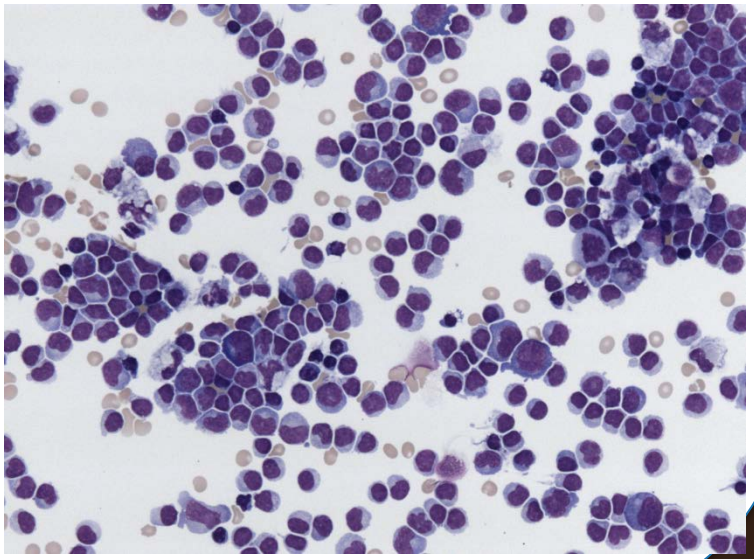

BUSH VETERINARY
NEUROLOGY SERVICE

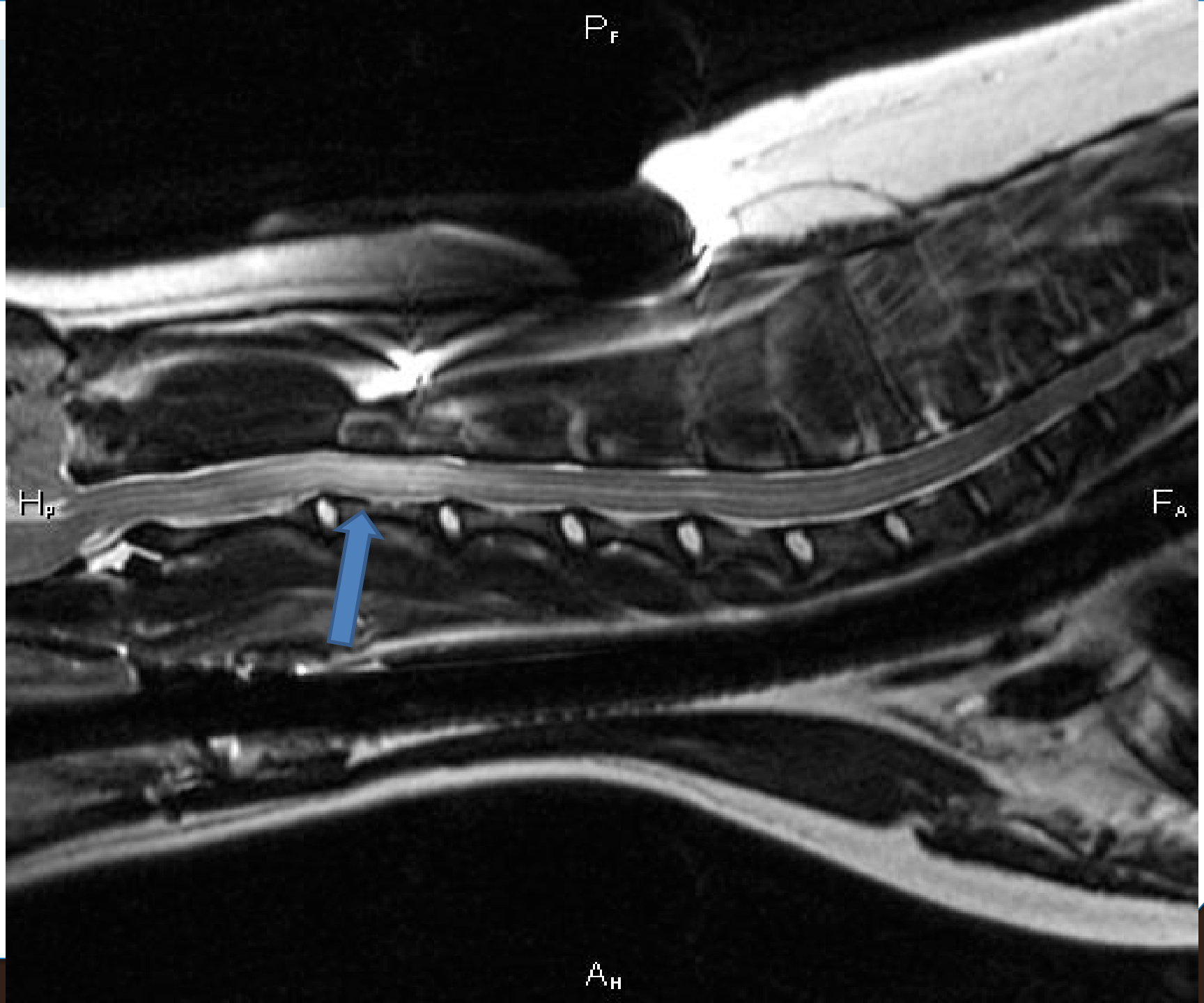
P_F
H_P
F_A
A_H

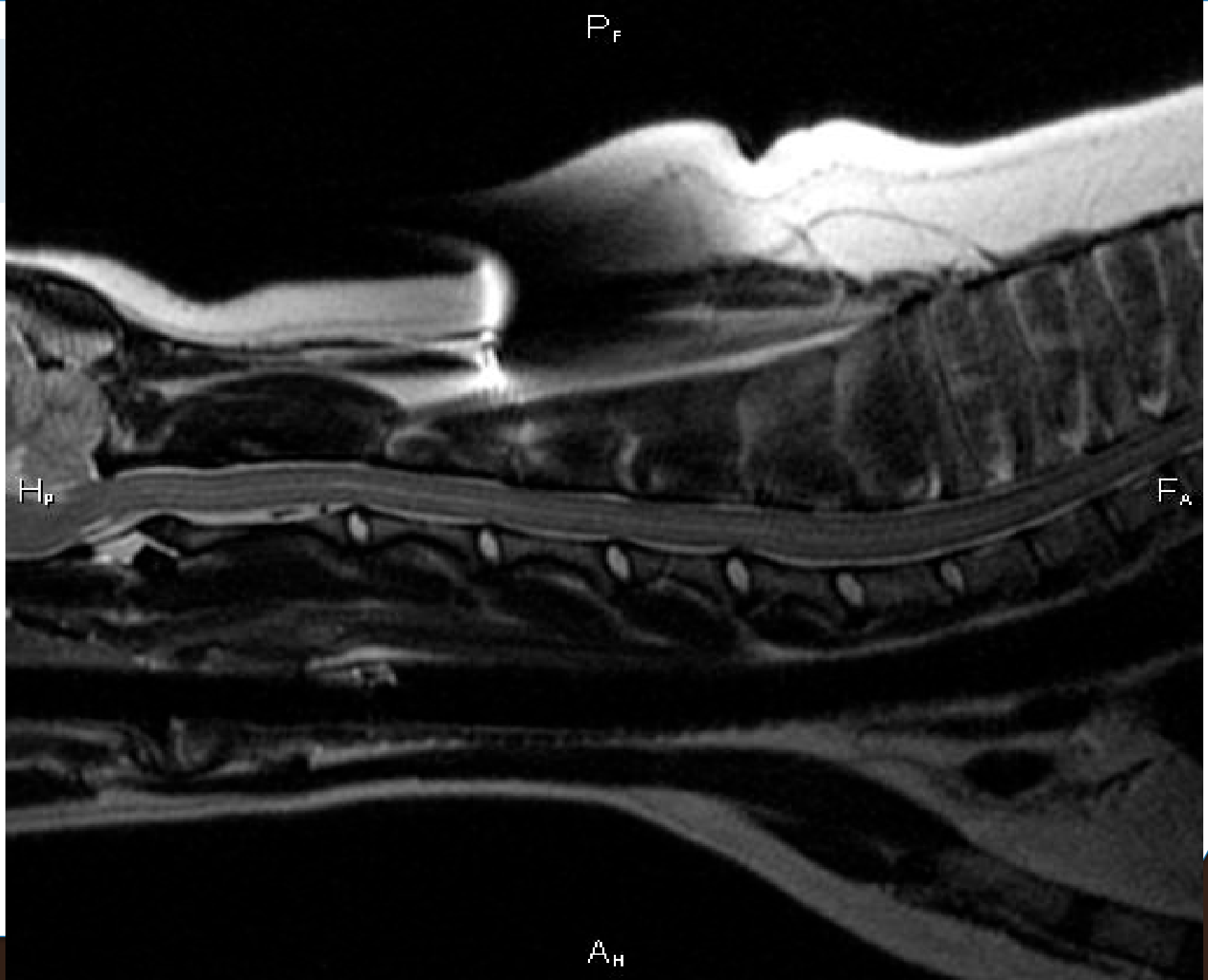
P F
H P
F A
A H

SRMA

- MRI
  - **Recommended*****
    - Often normal
    - +/- meningeal enhancement
- CSF analysis
  - Abnormal
  - Neutrophilic pleocytosis
- C-reactive protein (CRP)

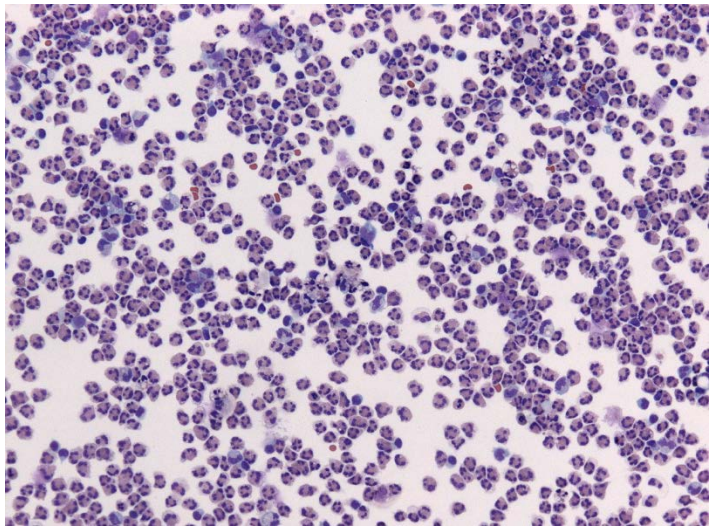

BUSH VETERINARY NEUROLOGY SERVICE

MUE / GME

- Treatment
  - Immune-suppression
    - Cytarabine / Cytosar
      - CRI or SQ
    - Cyclosporine
    - Prednisone
  - Antibiotic coverage
    - Doxycycline
    - Clindamycin

BUSH VETERINARY
NEUROLOGY SERVICE

SRMA

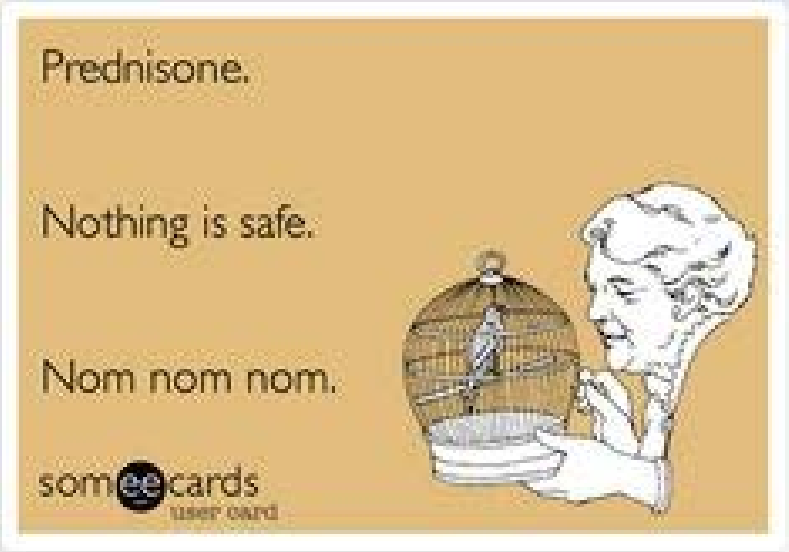

- Treatment
  - Steroids.
    - Prednisone
    - Initially immunosuppressive
    - Tapering course over 4-6 months
  - Analgesic therapy
  - +/- other immune-modulation
    - Cyclosporine
    - Azathioprine

BUSH VETERINARY
NEUROLOGY SERVICE

Prognoses

- **MUE / GME**
  - Guarded-to-fair
    - 70/30 rule
  - Relapse common
  - Repeat diagnostics
    - 3 months
    - **Heavily discounted**
    - Predictive of relapse
- **SRMA**
  - Good-to-excellent
  - Relapse uncommon

MUE / GME and SRMA

- The 4 Questions
  - **Onset?**
    - Acute
  - **Progression?**
    - Progressive
  - **Symmetry?**
    - Symmetric
  - **Painful?**
    - Absolutely

- V – Vascular
- I – Infectious / Inflammatory
- T – Trauma
- A – Anomaly
- M – Metabolic
- I – Idiopathic
- N – Neoplasia
- D – Degenerative

BUSH VETERINARY
NEUROLOGY SERVICE

What we won’t talk about…

- Spinal fractures
- Brachial plexus avulsions

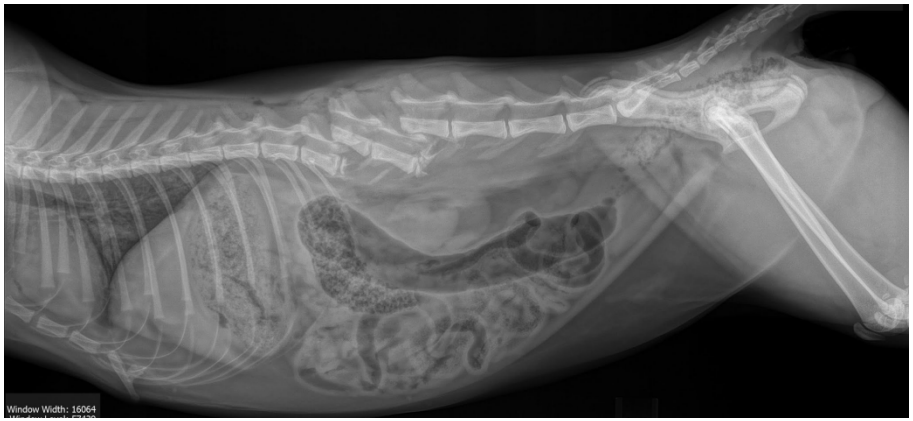

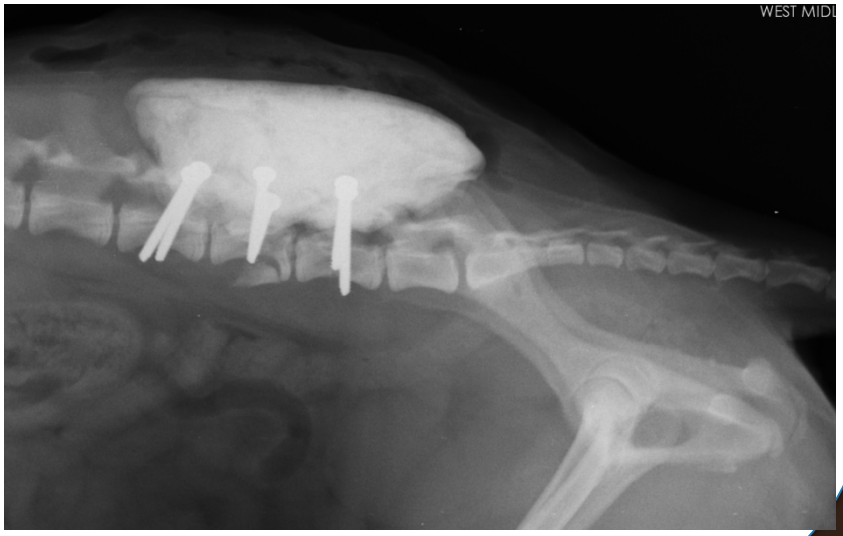

BUSH VETERINARY
NEUROLOGY SERVICE

Trauma

- <u>2 traumatic disc injuries</u>
  - Acute non-compressive nucleus pulposus extrusion (ANNPE)
    - AKA
      - Type 3 disc
      - Traumatic disc
      - Low volume, high velocity disc
      - Missile disc
  - Compressive hydrated disc rupture

Trauma

- <u>2 traumatic disc injuries</u>
  - Similarities
    - History of trauma / activity
    - Normal discs
  - Main difference
    - One is **compressive**
    - → benefits from surgery

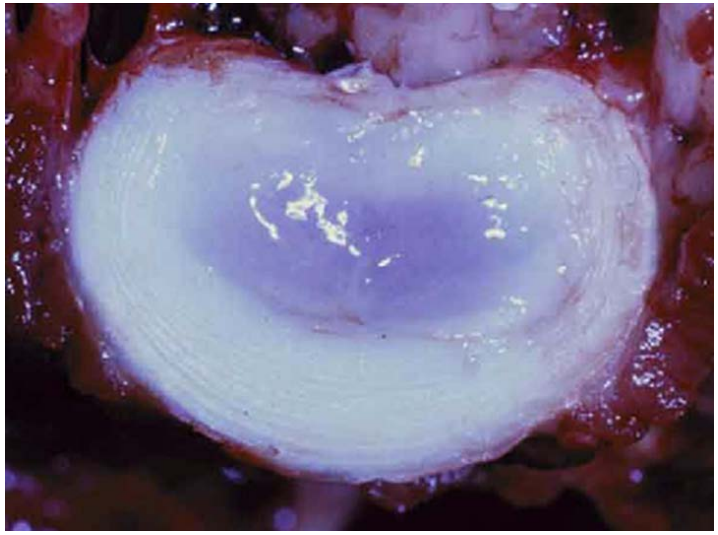

BUSH VETERINARY
NEUROLOGY SERVICE

ANNPE / Type 3 disc

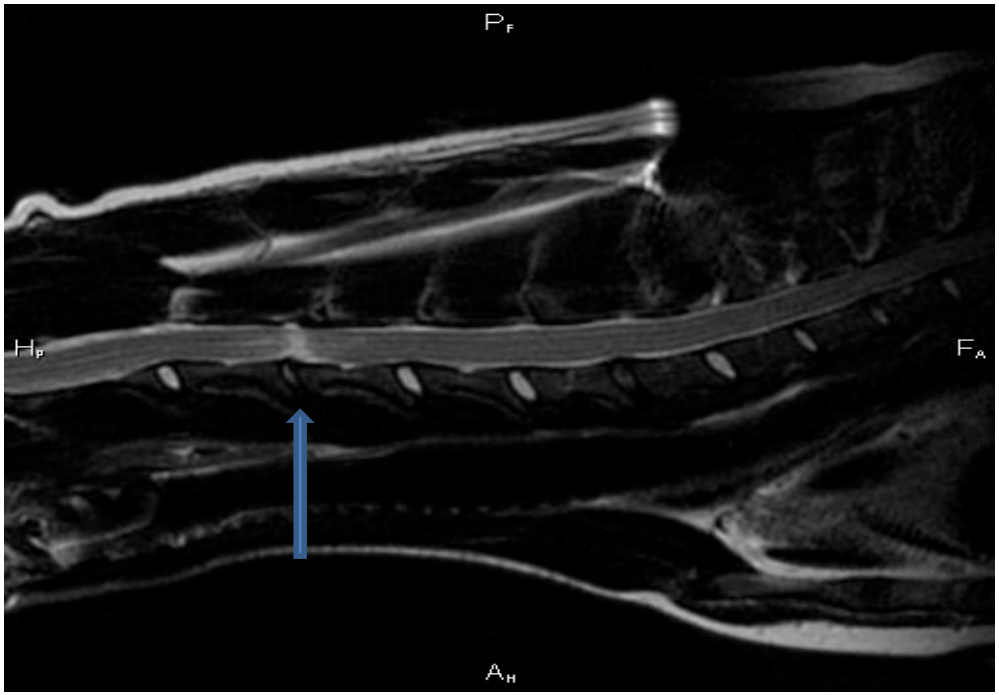

BUSH VETERINARY
NEUROLOGY SERVICE

ANNPE / Type 3 disc

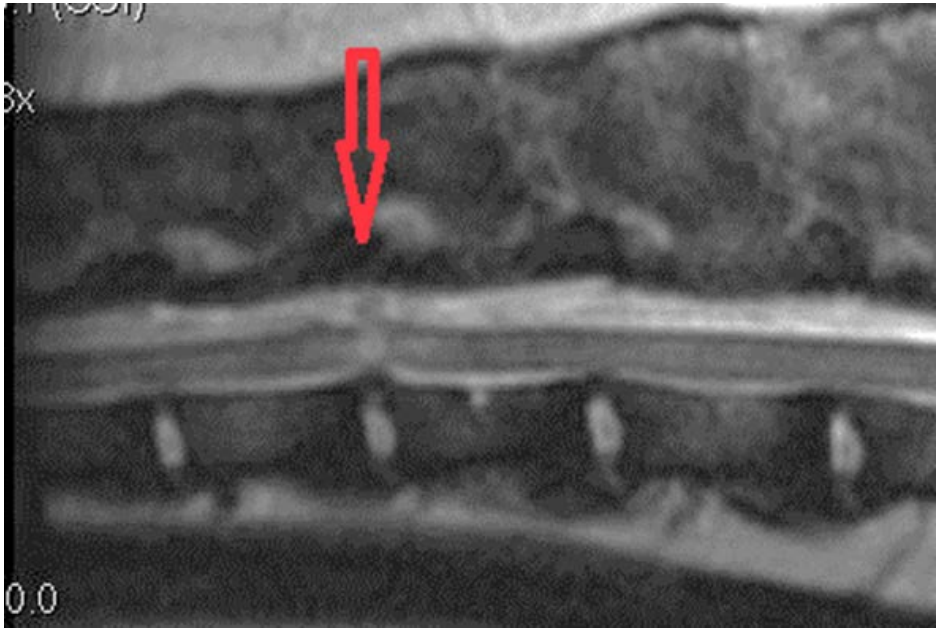

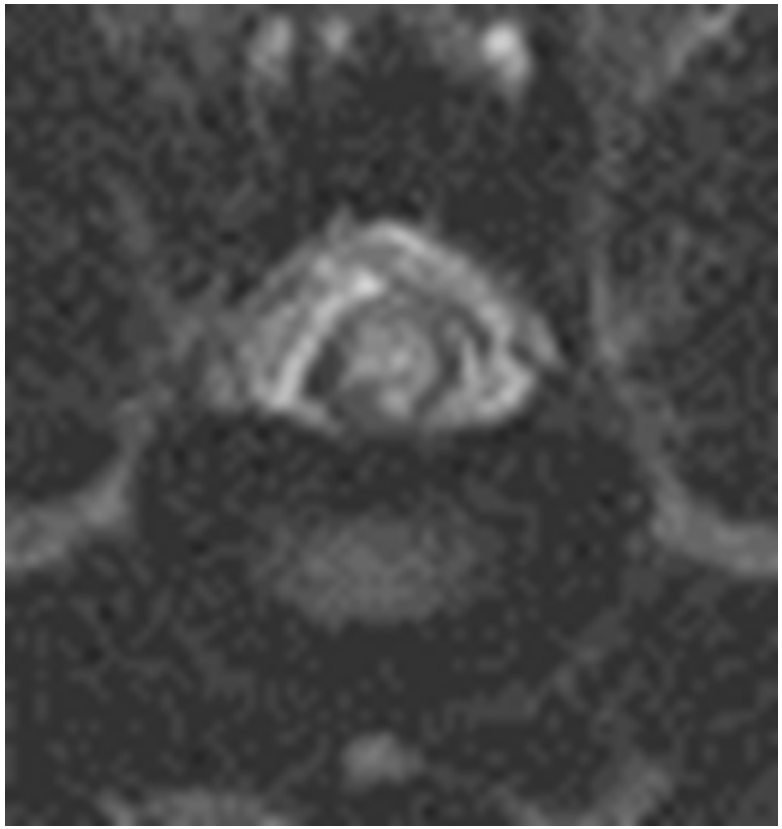

BUSH VETERINARY
NEUROLOGY SERVICE

Compressive / Hydrated Disc

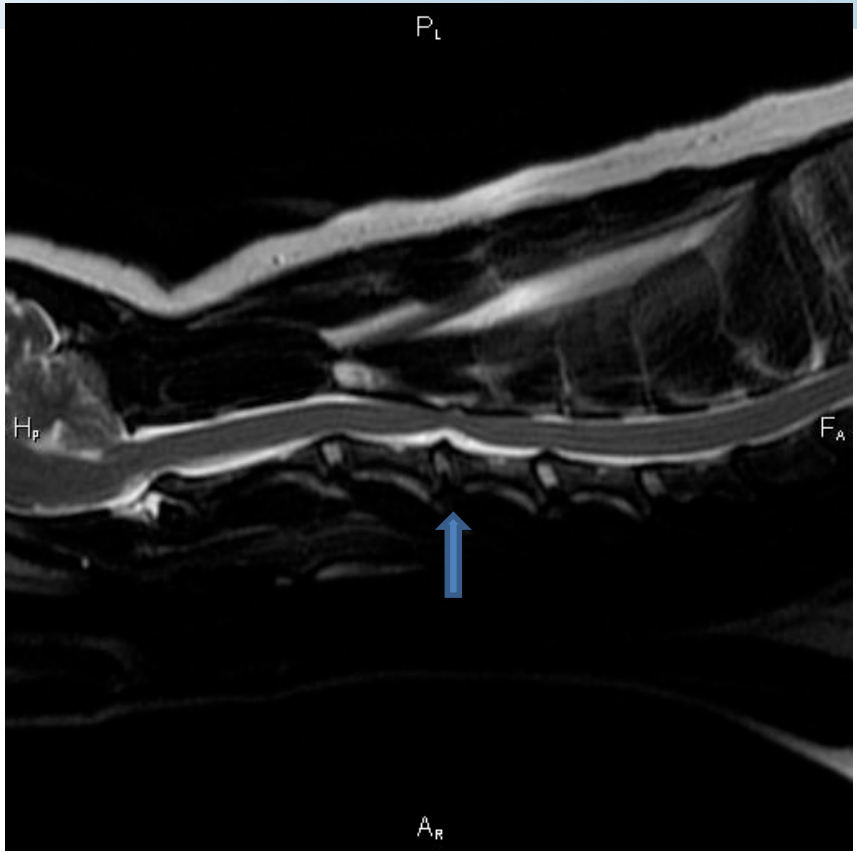

BUSH VETERINARY
NEUROLOGY SERVICE

ANNPE

- Treatment?
  - Supportive care
  - Physical therapy / Rehab
  - *No evidence to support use of NSAID / steroids*

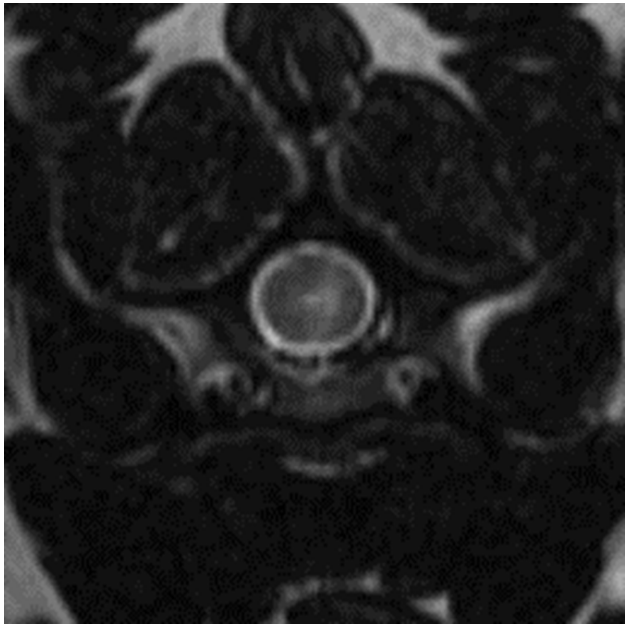

Compressive Hydrated Disc

- Treatment?
  - Depending on degree of compression
    - Surgery
      - Ventral slot
      - Dorsal laminectomy
      - Hemilaminectomy
    - Medical management
- Prognosis?

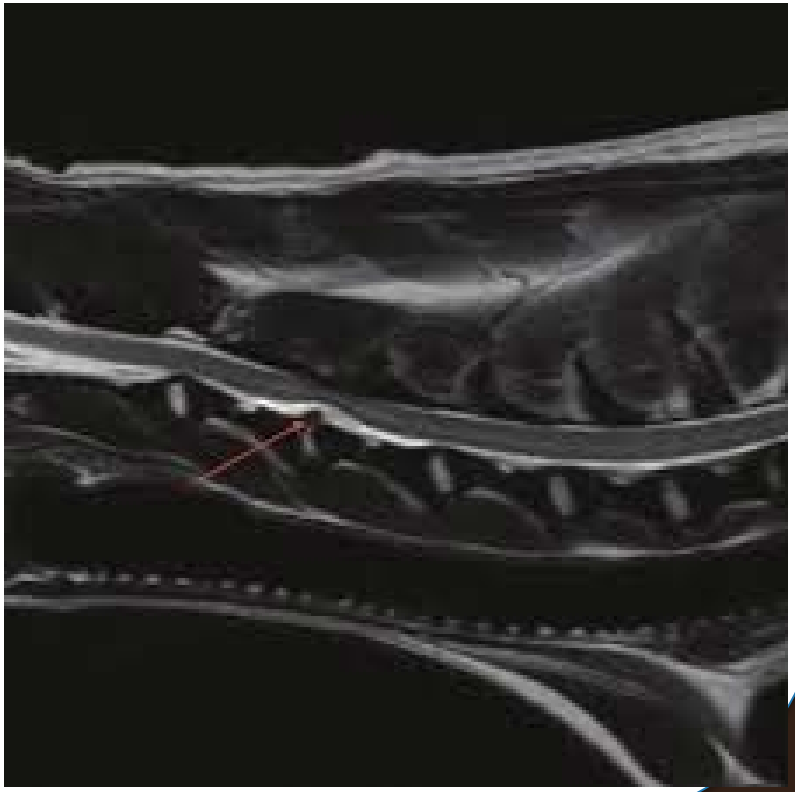

BUSH VETERINARY NEUROLOGY SERVICE

ANNPE (Type 3)

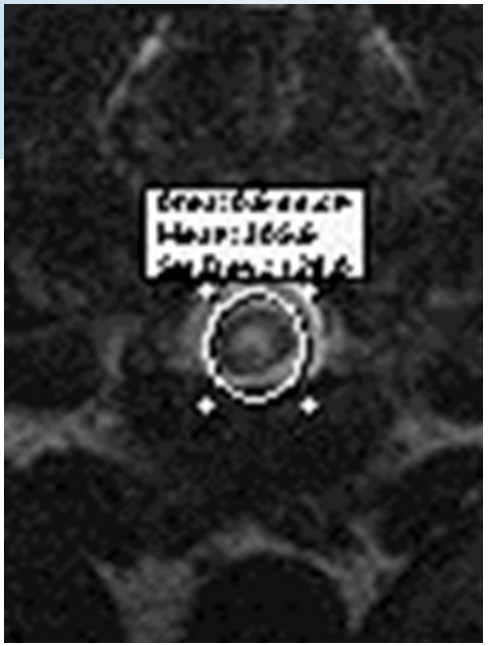

- De Risio et. al 2009
- 42 cases
- 67% of dogs had successful outcome
- Outcome factors
  - Severity of neurologic deficits
  - Extent of hyperintensity on sagittal and transverse T2-weighted images
- Cross-sectional area of intramedullary hyperintensity was best predictor of outcome

BUSH VETERINARY
NEUROLOGY SERVICE

Trauma

- The 4 Questions (ANNPE)
  - **Onset?**
    - Peracute
  - **Progression?**
    - Non-progressive
  - **Symmetry?**
    - Very commonly asymmetric
  - **Painful?**
    - Transient pain at onset
    - Non-painful
- The 4 Questions (Hydrated disc)
  - **Onset?**
    - Peracute-to-acute
  - **Progression?**
    - Progressive
  - **Symmetry?**
    - Symmetric, severe
  - **Painful?**
    - > 50% are painful

- V – Vascular
- I – Infectious / Inflammatory
- T – Trauma
- A – Anomaly
- M – Metabolic
- I – Idiopathic
- N – Neoplasia
- D – Degenerative

Next Time!

BUSH VETERINARY NEUROLOGY SERVICE

Take Home Points

- MRI is the best diagnostic modality to evaluate spinal cord health, determine an accurate prognosis and to plan appropriate therapy
- Ischemic myelopathy occurs in older cats and is often associated with concurrent systemic disease
  - Cervical ventroflexion DDX!
- C-reactive protein is a useful adjunctive diagnostic tool to screen and monitor for infectious or inflammatory spinal cord disease
- Repeating spinal diagnostics at 3 months in dogs with MUE is the best predictor of relapse

References

- Beltran E[1], Dennis R, Doyle V, de Stefani A, Holloway A, de Risio L. **Clinical and magnetic resonance imaging features of canine compressive cervical myelopathy with suspected hydrated nucleus pulposus extrusion.** J Small Anim Pract. 2012 Feb;53(2):101-7.
- Burkert BA[1], Kerwin SC, Hosgood GL, Pechman RD, Fontenelle JP. **Signalment and clinical features of diskospondylitis in dogs: 513 cases (1980-2001).** J Am Vet Med Assoc. 2005 Jul 15;227(2):268-75.
- De Risio L[1], Adams V, Dennis R, McConnell FJ, Platt SR. **Association of clinical and magnetic resonance imaging findings with outcome in dogs suspected to have ischemic myelopathy: 50 cases (2000-2006).** J Am Vet Med Assoc. 2008 Jul 1;233(1):129-35.
- De Risio L[1], Adams V, Dennis R, McConnell F, Platt S. **Magnetic resonance imaging findings and clinical associations in 52 dogs with suspected ischemic myelopathy.** J Vet Intern Med. 2007 Nov-Dec;21(6):1290-8.
- Harris JM[1], Chen AV, Tucker RL, Mattoon JS. **Clinical features and magnetic resonance imaging characteristics of diskospondylitis in dogs: 23 cases (1997-2010).** J Am Vet Med Assoc. 2013 Feb 1;242(3):359-65.

BUSH VETERINARY
NEUROLOGY SERVICE

References

- Lowrie M[1], Smith PM, Garosi L. **Meningoencephalitis of unknown origin: investigation of prognostic factors and outcome using a standard treatment protocol.** Vet Rec. 2013 May 18;172(20):527.
- Maiolini A[1], Carlson R, Schwartz M, Gandini G, Tipold A. **Determination of immunoglobulin A concentrations in the serum and cerebrospinal fluid of dogs: an estimation of its diagnostic value in canine steroid-responsive meningitis-arteritis.** Vet J. 2012 Feb;191(2):219-24.
- Simpson KM[1], De Risio L[2], Theobald A[2], Garosi L[1], Lowrie M[3], **Feline ischaemic myelopathy with a predilection for the cranial cervical spinal cord in older cats.** J Feline Med Surg. 2014 Dec;16(12):1001-6.
- Tipold A[1], Schatzberg SJ. **An update on steroid responsive meningitis-arteritis.** J Small Anim Pract. 2010 Mar;51(3):150-4.
- De Risio L[1], Adams V, Dennis R, McConnell FJ. **Association of clinical and magnetic resonance imaging findings with outcome in dogs with presumptive acute noncompressive nucleus pulposus extrusion: 42 cases (2000-2007).** J Am Vet Med Assoc. 2009 Feb 15;234(4):495-504.

BUSH VETERINARY
NEUROLOGY SERVICE

Any Questions??

BUSH VETERINARY
NEUROLOGY SERVICE